



7

## Bekken – anatomie en pathologie

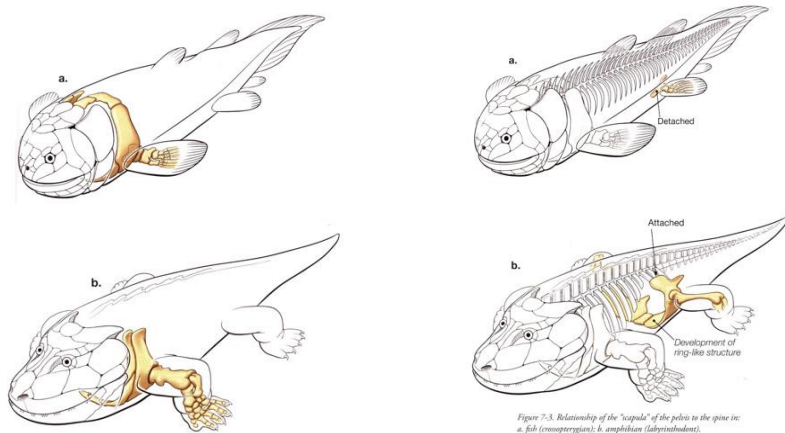
Opleiding fasciatherapie F.I.T.  
Module onderste extremiteit

Short description of content: Description of the pathology of the pelvis from myofascial perspective

Learning objectives: The student is familiar with the pathology of the pelvis and knows how to treat this from a myofascial perspective.



## Bekken van mobiel naar stabiel

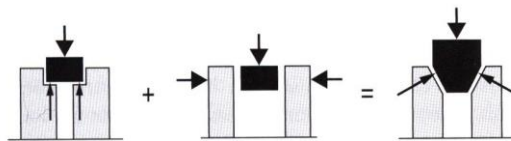


(Dimon 2011)

2

From mobile to stabile

Man was the first creature that could walk straight up and kill at a distance by throwing something. This was made possible by a no-frills no-fuss pelvis that has a minimum of moving parts and a maximum of strength and flexibility.



**Figure 2.2.5 •** Model of the self-locking mechanism. The combination of form closure and force closure establishes stability in the sacroiliac joint

Vleeming: form and force closure

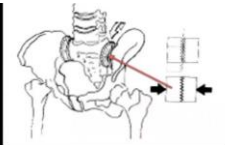
<<Form closure refers to a stable situation with closely fitting joint surfaces, where no extra forces are needed to maintain the state of the system, given the actual load situation. In this situation no lateral forces are needed to counterbalance the effects of the vertical load. With force closure a lateral force is needed.

<<Sacroiliac joint (ISG): ISG dysfunctions can occur primarily (usually after a misstep or fall) and are then easily accessible to joint-specific manual therapeutic treatment. If there is no lasting success after 2-3 mobilization treatments, ISG dysfunction is most likely secondary. Tension or shortening of the muscles pulling over the ISG (M. piriformis. Mm. Glutei, M. iliopsoas) influence the position of the ISG and can be a sustaining factor in ISG dysfunction. The causal treatment in these cases is the treatment of mTrPs. Gautschi 2019>>

Maladaptive changes might in turn lead to reduced force closure (involving a deficit in motor control of, for example, the sacroiliac joint) or excessive force closure (involving increased motor activation) resulting in a mechanism for ongoing peripheral pain sensitization, leading to chronic pain involving the sacroiliac and/or other pelvic structures.



## Sacrum zou uit het bekken vallen....



### Ratchet it Up!

Joint Has Some Ridges

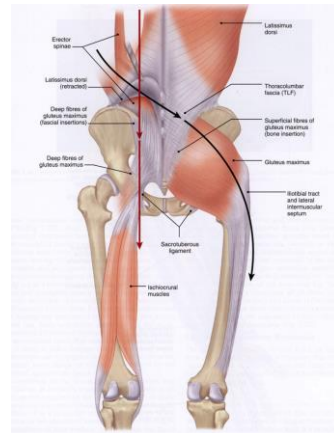

**But -**

It Is a Synovial joint  
and Would Be Slicker than an  
Oiled Cobblestone Street





## Bekken als tensegrity structuur





## Het bekken en bovenbeen

### Check:

- Piriformis
- Obturatorii
- Hamstrings
- QL

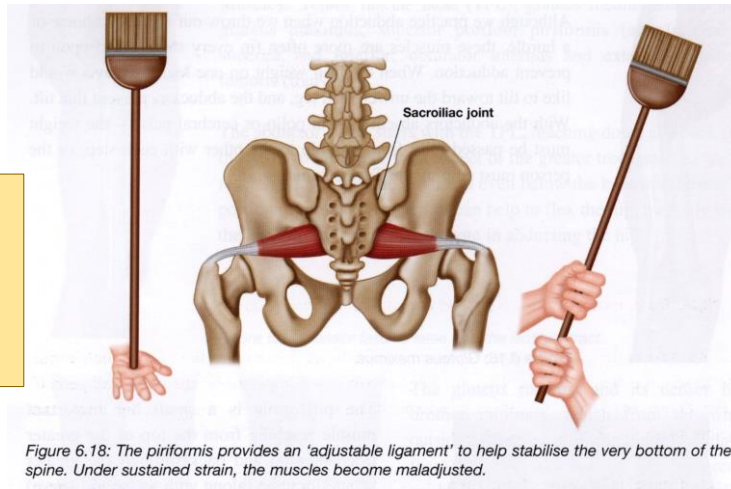


Figure 6.18: The piriformis provides an 'adjustable ligament' to help stabilise the very bottom of the spine. Under sustained strain, the muscles become maladjusted.

6

Sacrum is suspended inside the pelvis

<<Ida Rolf: the hip is the joint that determines symmetry. Balans hier is zeer belangrijk ook als het probleem hoger of lager is. Earls 2017>>

<<The idea of a support function of the Mm. obturatorii is also the work of B.Calais-Germain | 28 | supported. Your approach is the description of mm. obturatorii as a pelvic suspension system thanks to Fig. 2.12). Together with the pelvic floor muscles, the Mm. obturatorii a functional chain. This creates a kind of "hammock" for the pelvis, in that the obturator muscles fix the pelvis on the thighs and the pelvic floor "catches" the intestines. For the visa inspection we have to do the correct course of the Mm. consider obturatorii. The tendons of both muscles insert into the trochanteric fossa of the greater trochanter of the femur.

The Mm. obturatorii form a kind of "loop" around the ramus ossis ischii and corpus ossis ischii. This is reminiscent of the "suspension straps" of an old stroller (■ see Fig. 2.14). The basket could be thought of as a basin, the suspension straps as mm. obturatorii and the frame of the stroller as a femur. In practice it is extremely important to understand the tension and functionality of the Mm. check and

normalize obturatorii.

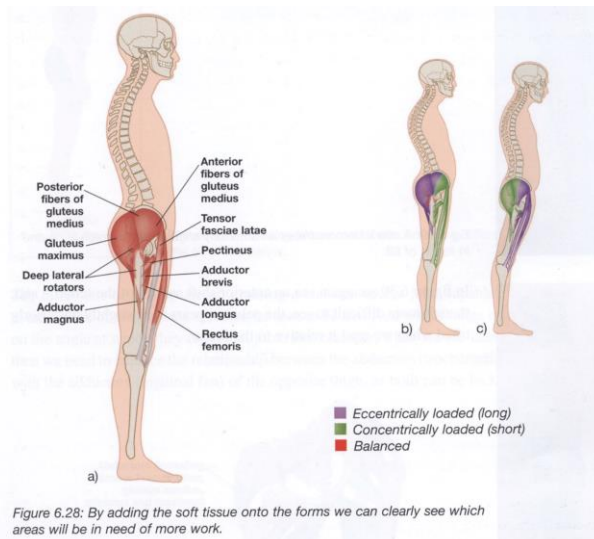
It is also important to take into account that the internal and external pudendal arteries and the pudendal nerve run in the fascial sheath of the internal obturatorius muscle. Tension problems of Mm. Obturatorii can therefore also be accompanied by irritation of the pudendal nerve and narrowing of the internal pudendal vessels, which can result in paraesthesia or congestion phenomena in the genital and perineal area Gautschi 2019>>



## Bekkenkanteling

Check:

- Psoas
- Glutei
- Qceps



(Earls, 2011)

Figure 6.28: By adding the soft tissue onto the forms we can clearly see which areas will be in need of more work.

7

The aim is not only to remove the pain but also to restore the myofascial balance

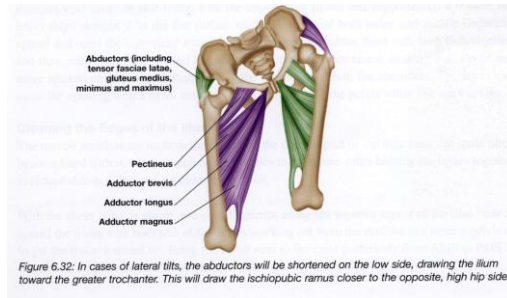




## Bekkenscheefstand

### Check:

- Adductoren
- Abductoren
- QL
- Psoas
- Voeten



(Earls, 2017)

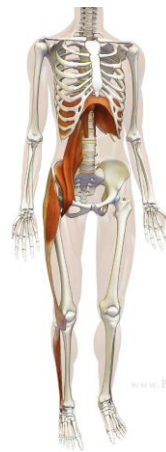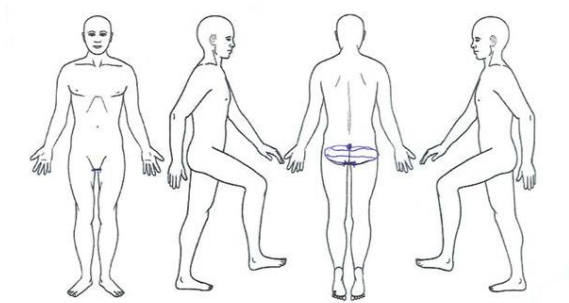
<<Obt. ext and gemelli are not only exorotators but also extensors and therefore tilt the basin backwards Obt. Int is a flexor and therefore tilts the pelvis forward Both piriformi stabilize the sacum / spine in the lateral direction  
Known abbreviations: pectinous for tilting forward and endo hip, quadratus for tilting back and exo. Right pectoralis often accompanies left piriformis.  
A-P Shifts: especially work with the feet. Earls 2017>>

<< It is often possible to release 'indirect' restrictions in the case of TrP's in the biceps femoris (head of fibula), pelvic floor, piriformis muscle, and elsewhere, after which it is usually found that restrictions of the sacroiliac joint are also resolved. Such chain reactions indicate that most restrictions of the SI joint are secondary. Lewit, 2010>>

TrP Referred pain to SI: QL, glutei, maar ook hamstrings, tensor, Qceps en soleus(!)



## Lokaal probleem?



9

Patient indicates very local pain, had treatment for some time focused only on that area. Further investigation revealed that there were myofascial problems in a much larger area: always look globally!



## SI problemen – primair of secundair?

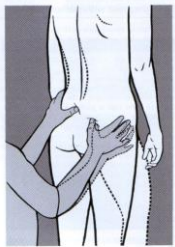
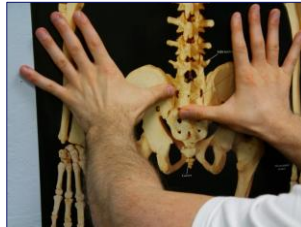
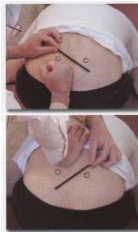Figure 4.7 • The spine sign



- SI eenzijdig hypermobiel
- SI gefixeerd (myogeen)
- SI gefixeerd (arthrogeen)
- SP instabiel

Botbruggen bij 30% van de mannen

10

<< The PS has less ability to resist shear/translation than the SIJ in that the joint surfaces are relatively flat; the PS has less form closure. The joint surfaces are bound by a fibrocartilaginous disc that is supported externally by superior, inferior, anterior, and posterior ligaments. The PS is vulnerable to shear forces in both the vertical and horizontal plane and relies on 'extra forces' or force closure (compression in the coronal plane), in addition to its passive restraints, for control of vertical shear (Cowan et al 2004). Lee, 2011>>

<< SI joint restriction occurs far more often as a secondary phenomenon than was previously assumed. It commonly reflects muscle fixation due to movement restriction of the fibular head with a TrP in the biceps femoris, or due to restrictions of L4/L5 as a result of TrP's in the piriformis and in the pelvic floor. Pelvic distortion is always a secondary symptom. Adolescent girls with pelvic distortion also frequently present with dysmenorrhea. Here the true cause is probably a dysfunction at the lumbosacral junction with TrP in the iliacus. Lewit, 2010 >>

<<Dar et al. (2008) <sup>TM</sup> examined the sacro-iliac joints of 287 individuals who did not have musculoskeletal disease. They visualized the pelvis using three-dimensional CT

scans and looked at any bone bridges present at the site of the sacroiliac joints. A bone bridge can be seen as a fusion between sacrum and pelvis. Movement is then no longer possible. They found bone bridges in 28% of men and 3% of women. Most bone bridges were found in older men:

31% of men between 60 and 80 had one or more bone bridges.

47% of men older than 80 had one or more bone bridges.

The researchers recommend being cautious about manipulating or mobilizing the sacroiliac joints in older people because the risk of injury could be greater than the therapeutic effect. Nugteren 2013>>

<< Pelvic distraction, thigh thrust, compression, and sacral thrust tests, in combination, are accurate in detecting the SI joint as a source of pain (Laslett et al. 2005; Laslett 2008). It is only necessary to use two of four of these tests to have the best predictive power of determining that the SI joint was the patient's pain source. When all tests do not provoke pain, the SI joint can be ruled out as a source of the pain.

Chapter 2 Michael Seffinger - Palpation reliability and validity Chaitow palpation>>



## Interne pathologie

Anorectal pain syndrome\*  
Bladder pain syndrome\*  
Clitoral pain syndrome  
Epididymal pain syndrome\*  
Interstitial cystitis (IC)  
Pelvic floor muscle pain\*  
Pelvic pain syndrome  
Penile pain syndrome  
Perineal pain syndrome\*  
Vestibular pain syndrome  
Vulvar pain syndrome

Post-vasectomy pain syndrome  
Prostate pain / chronic prostatitis\*  
'chronic pelvic pain syndrome'  
Pudendal pain syndrome  
Scrotal pain syndrome\*  
Testicular pain syndrome\*  
Urethral pain syndrome  
Vaginal pain syndrome

(Chaitow, 2012)

Note: Syndromes marked \* have no proven infection or other obvious pathology and are characterized by persistent, recurrent or episodic pain.

- Internist
- MDL arts
- Gynaecoloog

- Littekenweefsel
- Triggerpoints
- Spierspanning

11

How many of these are trigger point associated disorders?

How many of these are trigger point associated disorders? Area of the pelvic therapist, but not always trained in T/P treatment  
In a subsequent later study, [Sudhakar et al. \(2000\)](#) confirmed a relationship between muscle T/PS and CPP in men, identifying the most common location of T/PS: pubococcygeus or puboanalis (90%), external oblique (80%), rectus abdominus (75%), adductors (29%) and gluteus medius (28%). Other relevant muscles in which T/PS can contribute to CPP are levator ani, iliopsoas, quadratus lumborum, gluteus maximus and the thoracolumbar extensor muscles ([Simons et al. 1999](#), [Carter 2000](#), [Luderson 2000](#), [Higginbotham & Korman 2003a](#), [Chaitow 2007a](#), [Montenegro et al. 2008](#), [Anderson et al. 2009](#)).

One of the pioneers of manual approaches to CPP, [Simons \(1988\)](#) described how trigger points in the following areas can produce virtually identical referred pelvic pain:

The lower abdominal wall;  
In tissue overlying the pubic bone;  
In levator ani;  
Tissues lateral to the cervix;  
Close to vaginal cuff scar tissue more than 3 months after hysterectomy;  
The dorsal aspect of the sacrum.

Simons demonstrated, in a study involving 130 patients, that he was able to remove CPP in nearly 90% of cases by deactivating trigger points in these sites.

<Chronic pain syndrome: \* Persistent or recurrent, episodic rectal pain with associated rectal trigger points/tenderness related to symptoms of bowel dysfunction.

Bladder pain syndrome: \* Suprapubic pain related to bladder filling, accompanied by other symptoms such as increased daytime and night-time frequency, with no proven urinary infection or other obvious pathology. The European Society for the Study of ICPPS (ESSIC) publication places greater emphasis on the pain being perceived in the bladder ([Gansle, Mearns et al. 2001](#)).

Clitoral pain syndrome: \* Pain localized by point-pressure mapping to the clitoris.

Endometriosis-associated pain syndrome: Chronic or recurrent pelvic pain where endometriosis is present but does not fully explain all the symptoms ([Fall et al. 2010](#)).

Episodic pain syndrome: \* Persistent or recurrent episodic pain localized to the epididymis on examination. Associated with symptoms suggestive of urinary tract or sexual dysfunction. No proven epididymo-orchitis or other obvious pathology (a more specific definition than scrotal pain syndrome [Fall et al. 2010](#)).

Interstitial cystitis (IC): Within the EU guidelines, IC is included within genital bladder pain syndrome. It is frequently diagnosed by exclusion. Positive factors leading to a diagnosis of IC include: bladder pain (suprapubic, pelvic, urethral, vaginal or perineal) on bladder filling, relieved by emptying, and characterized by urgency, and (commonly) the finding of submucosal haemorrhage (glomerulations) on endoscopy. IC is immediately ruled out in the presence of a variety of pathological conditions, including bacterial infection ([Hamann et al. 1999](#), [Pestier & Fall 2007](#)).

Pelvic floor muscle pain: \* Persistent or recurrent, episodic, pelvic floor pain with associated trigger points, which is either related to the micturition cycle or associated with symptoms suggestive of urinary tract, bowel or sexual dysfunction.

Pelvic pain syndrome: \* Pain within the pelvis that is not primarily in the urethra. Absence of proven infection or other obvious pathology ([Fall et al. 2010](#)).

Perineal pain syndrome: \* Persistent or recurrent, episodic, perineal pain either related to the micturition cycle or associated with symptoms suggestive of urinary tract or sexual dysfunction.

Post-vasectomy pain syndrome: Scrotal pain syndrome that follows vasectomy.

Prostate pain syndrome: Persistent or recurrent episodic prostatic pain, associated with symptoms suggestive of urinary tract and/or sexual dysfunction ([Fall et al. 2010](#)). This definition is adapted from the National Institutes of Health (NIH) consensus definition and classification of prostatitis ([Kroger et al. 1999](#)) and includes conditions described as 'chronic pelvic pain syndrome'. Using the NIH classification system, prostate pain syndrome may be subdivided into type A (inflammatory) and type B (non-inflammatory).

Pudendal pain syndrome: A neuropathic-type pain arising in the distribution of the pudendal nerve with symptoms and signs of rectal, urinary tract or sexual dysfunction. (This is not the same as the well-defined pudendal neuralgia.)

Scrotal pain syndrome: \* Persistent or recurrent episodic scrotal pain associated with symptoms suggestive of urinary tract or sexual dysfunction. No proven epididymo-orchitis or other obvious pathology ([Abrams et al. 2003](#)). This may be unilateral or bilateral, and is a common complaint in urology clinics.

Testicular pain syndrome: \* Persistent or recurrent episodic pain localized to the testis on examination, which is associated with symptoms suggestive of urinary tract or sexual dysfunction. No proven epididymo-orchitis or other obvious pathology. This is a more specific definition than scrotal pain syndrome ([Abrams et al. 2003](#)).

Urethral pain syndrome: \* Persistent or recurrent episodic urethral pain, usually on voiding, with daytime frequency and nocturia ([Abrams et al. 2003](#)).

Vaginal pain syndrome: \* Persistent or recurrent episodic vaginal pain associated with symptoms suggestive of urinary tract or sexual dysfunction.

Vestibular pain syndrome (formerly vulval vestibulitis): Refers to pain that can be localized by point-pressure mapping to one or more portions of the vulval vestibule.

Vulvar pain syndrome: Subdivided into generalized and localized syndromes:

Generalized (formerly dyspareunia, vulvodynia): Refers to vulval burning or pain that cannot be consistently and tightly localized by point-pressure 'mapping' by probing with a cotton-tipped applicator or similar instrument. The vulval vestibule may be involved but the discomfort is not limited to the vestibule.

Localized: Refers to pain that can be consistently and tightly localized by point-pressure 'mapping' to one or more portions of the vulva. Clinically, the pain usually occurs as a result of provocation (touch, pressure or friction) ([Abrams et al. 2003](#)).

Chaitow in Chaitow 2012 H1.1>

The matrix of areolar connective tissue also serves to deposit collagen for the formation of scar tissue. Commonly, women with CPP have undergone laparoscopic investigation as an attempt to identify pain generators. The trocar (a surgical instrument) may have been used through the umbilicus, in the suprapubic region, or other lower abdominal sites. Formation of scar tissue here can directly create restriction of the iliohypogastric and ilioinguinal nerves ([Howard 2000](#)). Peri-umbilical and suprapubic subcutaneous paresthesias secondary to incisions have been associated with urinary urgency, frequency and dysuria ([Fitzgerald & Kozlowski 2001](#)).

<In the case of excess pressure, in the abdomen the body endeavours to compensate for this. The body naturally has more than one option available, such as placing the diaphragm in the elevated position, relaxing the abdominal musculature, extending the upper body, lordosing the lumbar spine and tilting the pelvis in anteversion. In the case of adhesions and scars in the abdomen, the body likewise endeavours to compensate for these tensions. Similarly, it obviously has several possible ways of compensating for the abdominal adhesions. Examples of this are positioning the diaphragm at the low position, tensing the abdominal muscles, infecting the upper body, lordosing the lumbar spine and tilting the pelvis in anteversion. Meert 2012.140>

<< Gross pathology, as measured by the latest medical instruments, has not been able to explain the degree of suffering caused by these disorders.

Doctors often tell patients with chronic pelvic pain syndromes that they can find little or nothing wrong with them. Wise 2018>>

<Chronic prostatitis

Associated inflammatory tract complaints such as irritative bowel disorder, constipation, dietary exacerbations, and bowel function may point to further clarifying aspects of the disorder. Further, the psychosocial medical history should probe for genetic or acquired personality types: tense, anxious, chronic tension-holding patterns, possible childhood issues of sexual or physical abuse, traumatic toilet training, abnormal bowel patterns, teen sexual problems, excessive masturbation, suppressed homosexuality, excessive weight lifting, gymnastic maneuvers, and activities such as dance training.

Chronic prostatitis is caused by bacteria in only 5 percent of cases of pelvic pain.

While very small percentages (3 to 10 percent) of patients have been found to carry certain unusual organisms, there have never been convincing studies to prove that these organisms are specific causative agents in prostatitis.

This information again refutes the idea that we are dealing with a painful bladder pain syndrome. It is frequently diagnosed by exclusion. Positive factors leading to a diagnosis of IC include: bladder pain (suprapubic, pelvic, urethral, vaginal or perineal) on bladder filling, relieved by emptying, and characterized by urgency, and (commonly) the finding of submucosal haemorrhage (glomerulations) on endoscopy. IC is immediately ruled out in the presence of a variety of pathological conditions, including bacterial infection ([Hamann et al. 1999](#), [Pestier & Fall 2007](#)).

As we do not have proof of infectious agents causing chronic pelvic pain syndrome, the unanswered question remains: 'What is causing the inflammation?' Many investigators believe that it has to do with dysfunction of the voiding mechanism: an imbalance in the urinary muscle control causes reflux or pressure of urine and hence toxic substances of urine backing up into the prostate gland ducts to create an inflammatory and irritated condition. In simple language, tension in the pelvic muscles may be inhibiting the free flow of urine, causing it to reflux or back up into the prostate.

The best way to look at the prostate gland tissue is to use transrectal ultrasound (TRUS). This method of evaluation can often be quite valuable in demonstrating inflamed tissue, the presence of stones in the ducts (representing urinary mineral deposits), swelling and thickening of seminal vesicles (semen storage organs behind the prostate), and accurate measurement of the size of the gland. Japanese investigators have used color Doppler images and angiography to dye in blood vessels to evaluate chronic pelvic pain. They demonstrated excellent three-dimensional graphic images of veins around the prostate and found considerable congestion in these veins behind the bladder and along the sides of the prostate in patients suffering with pain. In these patients, the veins on the surface of the prostate were much thicker in diameter than those in subjects with no pain. This basically represents varicose veins of the prostate. It is suggestive of heightened tension in the muscles of the pelvic floor and is supportive of our view that chronic pelvic pain syndromes are associated with muscle tension.

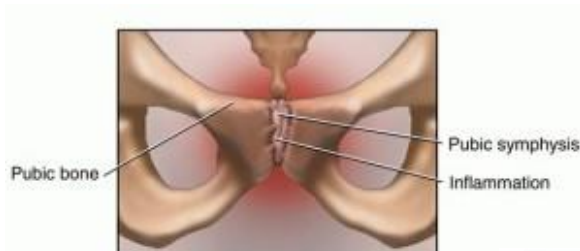We do not recommend pudendal nerve injections or pudendal nerve surgery. Certainly, any surgical approach to alleviate this condition must rely on documentation of nerve dysfunction as measured by nerve conduction studies. It appears, however, that less than 50 percent of patients experience any reduction of their pain with surgery. In our experience, most patients undergoing surgical procedures for muscle-based pelvic pain report such procedures and often report less-than-satisfactory results, a high level of new symptoms, and compromised pelvic floor stability. We have never seen a patient whose symptoms have resolved after pudendal nerve entrapment surgery.

In 1988 Dr. Harry C. Miller studied 231 men who had complaints typical of CPPS. Sixty percent or 134 of these patients were followed carefully and managed only with stress control. With this psychological approach alone, 86 percent of the patients reported that they were better, much better, or cured. Most important, repeat cultures, prostatic massages, instrumentation, and medications were not utilized at all in this group of patients, as Miller relied solely on stress management.

Wise ~2018>>

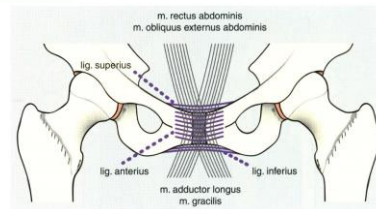


## Osteitis Pubica



### Check:

- Buikspieren, pyramidalis
- Balans adductoren/abductoren
- Heupmobiliteit



12

<<Osteitis pubis (pubalgia or athletic pubalgia) used to be considered a 'disease' (note its inclusion in Table 5.1) and is now thought to be the result of 'chronic overload or impaction trauma' (Gilmore 1998, Kunduracioglu et al 2007, Verrall et al 2001), secondary to repetitive jumping, twisting, or turning motions during sprinting, cutting, and kicking tasks. This chronic overload is thought to be due to an imbalance between the abdominal and adductor muscles (Robinson et al 2004, Rodriguez et al 2001). The irregularities of the bony margins of the PS and sclerosis of the pubic ramus are evident via magnetic resonance imaging (MRI) and SPECT-CT. Lee, 2011>>

### <<Osteitis pubis

The name osteitis pubis (OP) suggests inflammation, however it appears to involve a degenerative rather than an inflammatory process, characterized by symphysis pubis (SP) pain, with occasional referral along the adductor muscles to the hip, superiorly to the lower abdominal region and posteriorly towards the perineum and scrotum in men ([Hackney 1993](#)). OP can produce symptoms of exercise-induced pain in the inner thigh and abdominal area which come on gradually and worsen as the activity progresses. Examination reveals tenderness over the SP and this usually needs to be present to confirm a diagnosis ([Reid 1992](#)). Confusingly resisted hip adduction or trunk flexion may also reproduce the symptoms, which is usually indicative of

muscular lesions. Plain film radiographs commonly reveal sclerosis of the pubic bones; with occasional widening of the symphysis, with laxity on stork views >2 mm ([Harris & Murray 1974](#)). However, X-rays have poor construct validity as often changes on X-ray do not correlate with symptoms and there are positive radiographic findings found in asymptomatic individuals ([Hackney 1993](#)). Bone and MRI scans correlate better with symptoms than radiographic appearance, with the ability of MRI scans to show bone marrow oedema into the pubic bones and detachment of anterior fascial layer, which is continuous with fascia overlying adductor muscles and the inguinal ligament ([Karlsson & Jerre 1997](#)). OP is generally thought of as the end result of an overuse continuum, resulting in excessive and repetitive strain of the SP and pelvis ([Cunningham et al. 2007](#), [Pizzari et al. 2008](#)). There is limited evidence of proven risk factors for OP in the literature although greater hip abductor to adductor muscle strength ratios and decreased total rotation range of hip motion have been implicated ([Maffey & Emery 2007](#), [Verrall et al. 2001](#)).

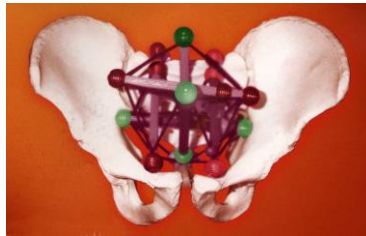
Lower-quadrant biomechanical abnormalities such as hypermobility, intrapelvic asymmetry and technique deficits are also said to play a role in the onset of OP, but to date there are no published trials to support this clinical observation ([Reid 1992](#), [Pizzari et al. 2008](#)). Taylor in Chaitow 2012 H6>>

osteitis pubis: repetitive trauma disorder associated with sports



## Research: prolaps

Development of a biotensegrity focused therapy for the treatment of pelvic organ prolapse:  
A retrospective case series  
Anna Crowle, Clare Harley. Journal of Bodywork & Movement Therapies 24 (2020) 115e125



In this small sample of women, we have demonstrated that the symptoms of pelvic organ prolapse were reduced and in some cases resolved whilst receiving biotensegrity-focused therapy. Considering pelvic tension, restrictions, and tensional pulls within the vagina and pelvic floor is likely to be important in advancing current treatments for pelvic organ prolapse.

13

Development of a biotensegrity focused therapy for the treatment of pelvic organ prolapse: A retrospective case series. Anna Crowle, Clare Harley. Journal of Bodywork & Movement Therapies 24 (2020) 115e125

Pelvic organ prolapse (POP), the bulging of one or more of the pelvic organs into the vagina, is a common condition with reported prevalence amongst women of approximately 32e41% (Handa et al., 2004; Hendrix et al., 2002). Symptoms typically include a sensation of a bulge in the vagina, pelvic pain, a dragging sensation, obstructive defecation, urinary incontinence or leakage, and sexual dysfunction (Chan et al., 2012; Espuna-Pons et al., 2014; Fritel et al., 2009). There is some evidence suggesting that pelvic floor muscle training may help to elevate pelvic organs and reduce the symptoms of POP (Li et al., 2016) but the efficacy of these exercises is limited with approximately 20e30% of women reporting benefit (Braekken et al., 2010; Ouchi et al., 2017).

Current treatments for POP aim to correct what is believed to be a weakness of pelvic tissue (Hagen et al., 2006; Word et al., 2009). The authors propose an alternative perspective, aligning with the biotensegrity view of the musculoskeletal system (Levin, 1981) that POP may be caused by pelvic tissue tension that disrupts pelvic



tissue equilibrium and pulls organs out of alignment.

The 'fascial continuity model' (de las Penas and Pilat, ~ 2011) for example, explains how disruptions to pelvic fascia may disrupt balanced equilibrium in the pelvis, affecting load transfer and leading to numerous problems including prolapse of pelvic organs into the vagina. Applying biotensegrity principles to POP would suggest that following pelvic injury (e.g., birth related scarring) excessive tension within pelvic tissues may pull organs into a place of discomfort or reduced functionality. Myofascial release (MFR) is one technique that is thought to reduce tensions and restrictions in tissue and several studies suggest it may be an effective treatment for a range of musculoskeletal conditions (Ajimsha et al., 2015; McKenney et al., 2013) including pelvic floor pain, interstitial cystitis, and prostatitis (Anderson et al 2005, 2011; FitzGerald et al., 2012). The aim of the present study is to describe the stages of development of the biotensegrity-focused therapy method and to explore how this new treatment may benefit women living with POP.

. In Cohort 1, observations were made during pelvic tissue palpation that scarring and areas of tension may be associated with prolapse symptoms. For example, when investigating birth scars or bands of tension within the pelvis some patients commented that palpation of these areas replicated the same sensation as their prolapse symptom. This led to these areas being targeted for release during treatment. It was also observed in this cohort of patients that the side to which the prolapsing organ had moved often corresponded with the least elastic side of the pelvic floor. Due to the above observations, there was increased focus on assessing and treating pelvic tissue tension in Cohort 2 (October 2016 to October 2017) and there was a reduced focus on the more traditional physiotherapy interventions.

Across the whole sample of 23 patients, 12 (52%) patients were assessed by the treating therapist to have no detectable prolapse by the last treatment session. Of these, seven confirmed that they had no sensation of prolapse and five reported some or occasional sensation of prolapse alongside mild symptoms. It was observed that urethroceles were more often assessed to have resolved fully compared to cervical descent and rectoceles. The number of prolapses fully resolved by the last treatment were: 9/10 (90%) urethrocele; 12/14 (86%) cystocele; 5/7 (71%) cervical descent; and 6/ 17 (35%) rectocele. Pelvic floor grade was also observed to increase during treatment. Across the sample at baseline median pelvic floor grade was 2 (range 0e3) increasing to 3 (range 2e4) by the last treatment session. The median number of treatments received across the sample was five (range 3e8) over a median period of 3 (range 1e8) months. The number of treatments received was determined by patients following discussion with the therapist about their functional goals and priorities, therefore the number of treatments received varied across the sample. The median number of treatments received was five (range 3e8) over a median period of three (range 1e8) months. This is substantially fewer treatments than the 12e16

weekly sessions that are typically prescribed in pelvic floor muscle training studies (Li et al., 2016). By the last treatment session an improvement in prolapse was observed for all women in the current study. Improvement was defined as the treating therapist observing a reduction in prolapse grade by the last treatment session alongside an improvement in patients' self-reported symptoms (e.g., reduced pain; decreased sensation of prolapse including a bulge in the vagina, sensation of dragging, heaviness, or pressure in the pelvis; improved bowel function; or improved urinary function).


. Observations during BFT suggested that tight internal pelvic tissue may have reduced the efficiency, power, and speed of pelvic floor contractions and prevented full hiatus closure and release. This aligns with previous research showing the importance of lengthening pelvic floor tissues before strengthening (FitzGerald and Kotarinos, 2003; Stein and Hughes, 2016). The role of PFMT alongside or after BFT is not currently understood and needs investigation in future research.

The findings from this case series align with other recent studies demonstrating positive outcomes of using women's health physiotherapy approaches that consider pelvic tension, alignment, and biotensegrity. These include abdomino-visceral release (Horton, 2015), treating internal trigger points for pain, ensuring pelvic floor tissues have full length as well as strength (Herrerra, 2014; Stein and Hughes, 2016), and postural optimization to improve pelvic and abdominal function (Lee et al., 2008). The findings of the current study also corroborate previous findings by Whelan (2013), who presented a case series of 12 women with pelvic organ prolapse who responded positively to manual therapy to the pelvic floor, as well as standard pelvic floor muscle training.

In this small sample of women, we have demonstrated that the symptoms of pelvic organ prolapse were reduced and in some cases resolved whilst receiving biotensegrity-focused therapy. Considering pelvic tension, restrictions, and tensional pulls within the vagina and pelvic floor is likely to be important in advancing current treatments for pelvic organ prolapse. Further research is needed to fully understand the mechanisms, efficacy, and longerterm outcomes for women receiving this treatment approach.



## Sway



*“fear is the basic shortener, tightener, traumatizer, and killer,  
headlong enthusiasm is its counterpart.”*

Karrash 2012<sup>14</sup>

<<Chronic tension in your hips and pelvis can make it difficult to feel motion in this area. Such tension can be due to cultural beliefs about beauty and sexuality. Because our culture decrees that thin is beautiful, many women tighten the muscles around their hips in an attempt to appear slender. People who are overweight compress this region to mask sensations of jiggling fat in the thighs or belly. Because our culture construes pelvic motion as female, men develop hip tension to avoid appearing feminine. Hip tension can also be an attempt to conceal the potency of the pelvic region by holding it immobile. The less we move any part of our body the less we feel it, to the extent that it can seem to be invisible. Any experience of sexual trauma increases the likelihood of hip and pelvic tension.

Movements of the arms and shoulders reflect our connections with others: how we give, receive, and protect ourselves. With meaningful gestures like these, the shoulders act as gatekeepers for the heart. We all know how it feels to be given a "cold shoulder." We may also have felt the weight of shouldering too many responsibilities.>>

<< Objects pull on my muscles from the outside, and my emotions pull on my muscles from the inside.

The two basic reflex responses – to withdraw and avoid, or to extend and explore. These inner tendencies are eventually faithfully mirrored in stiff, braced, defensive bodies or relaxed open bodies. Juhan 2003>>

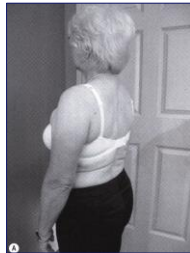<<Fear is the basic shortener, tightener, traumatizer, and killer, headlong enthusiasm is its counterpart. Karrash 2012>>

<<The major contributing factor involves a chronically knotted up, contracted pelvis—typically a physical response to years of worry—that leads to tight, irritated pelvic floor tissue, leading to a reflex response in the pelvic tissue of protective guarding that creates a self-feeding cycle that gives pelvic pain a life of its own. In what we can call pelvic pain related to pelvic floor dysfunction, sore pelvic floor tissue once established doesn't have a chance to heal the way other sore human tissue heals. You can think about the ongoing reflex protective guarding of irritated, sore pelvic tissue as a kind of ongoing pelvic charley horse. This chronic charley horse keeps the pelvic tissue irritated and preventing its otherwise natural healing. Ongoing pain from this sore tissue leads to protective pelvic muscle guarding, anxiety, continued dysfunctional protective guarding, and chronic painful tissue irritation.

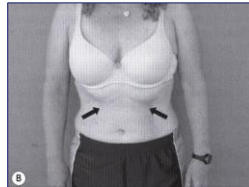Wise 2018>>



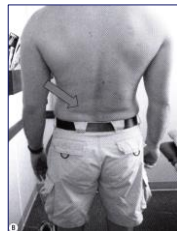## Emoties



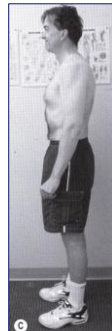back



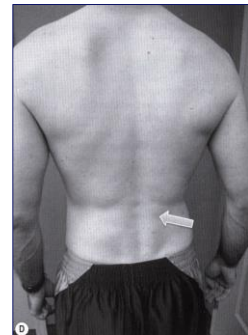
chest



butt



trunk



trunk -unilateral

gripping

(Lee, 2011)

15

< Basically, most people want the areas of the genitals and rectum to work but don't want to know much about them or to have to pay any attention to them.

These areas of the body are not treated with much appreciation. This is a truth that is reflected in how we word profanities. What do we call people with whom we are angry? Usually terms related to defecation or procreation. Indeed, these are terms of denigration. In our culture, the genitals and rectum are shrouded in shame and guilt. When a pelvis becomes chronically sore and irritated, sufferers often feel alone and afraid and are reluctant to share their experience, especially as they find neither a doctor nor a friend who can really understand their symptoms.

## Depression

- \* For many patients who are in the throes of pelvic pain, the thought that it will never go away triggers depression.
- \* When doctors cannot help, and one sees no light at the end of the tunnel, depression or anxious depression is the rule rather than the exception.
- \* Depression involves the feeling of helplessness about changing what feels critically wrong in one's life.

### Anxiety and Catastrophic Thinking (Projecting Catastrophe into the Future)

- \* The most difficult part of pelvic pain tends to be the catastrophic thought that it will never go away.
- \* Anxiety and catastrophic thinking distract patients' attention away from life, can paint an unacceptable picture of the future, and strongly arouse the nervous system, which in turn can increase pain.
- \* Pelvic pain typically occurs in individuals who tend to be anxious and catastrophize.

### Social Withdrawal and Difficulty in Intimate Relations

- \* The withdrawal results from chronic pain and its ability to distract the person from any enjoyment of the moment.
- \* Chronic pelvic pain takes a major toll on relationships in that the pain makes it very difficult to be fully present and enjoy the company of one's partner, family, or friends.

### Impairment of Self-Esteem

- \* Self-esteem almost always declines when one has pelvic pain.
- \* Men and women with chronic pelvic pain often worry that no one will want to be with them or that they will not get to do the things they wanted to do with their lives.

### Sleep Disturbance

- \* Sleep disturbance is common.
- \* Patients who tend to wake up to urinate during the night, or wake because of pain and anxiety, are deprived of sleep because they have difficulty going back to sleep having once woken up in an aroused and distressed state.
- \* At Stanford, we published a paper about the precipitous rise in Cortisol in the morning among pelvic pain patients.

The tendency to focus tension in the pelvic muscles is not an accident. Some have

suggested that a person's inclination to focus tension in the pelvic muscles may begin with toilet training. The child is able to stop his parent's reaction to soiling by tightening his pelvic muscles. Over time, tightening the pelvis becomes a conditioned reaction to any situation in which anxiety arises. This idea of focusing tension in the pelvic muscles as a result of early toilet training is simply an idea, and we do not propose that it be taken as fact. It is, however, a compelling explanation of how pelvic tension may well begin early in life in some of our patients. Wise 2018>>

<<The central nervous system responds with a wide variety of responses to pain; consequently different strategies for standing posture will be found.

- (A) The posture of a back-gripper. Note the posterior thoracic tilt and extension of the thoracic and lumbar spines.
- (B) The posture of a chest-gripper. Note the narrowing of the infrasternal angle and the classical vertical crease (arrows) of the lateral abdominal wall. This neuromuscular response tends to result in an anterior thoracic tilt (flexion of the thoracic spine) and the resultant lumbar posture depends on how the individual adapts to the resultant flexion force.
- (C) The posture of a trunk-gripper. Both the flexors and extensors of the trunk are overactive in this posture, and although it appears to be neutral it is extremely compressive.
- (D) Unilateral back-gripper. Note the increased tone in the right erector spinae (arrow).
- (E) butt-gripper

From the evidence, it is known that the changes in motor control that occur with actual, perceived, and/or experimentally induced lumbopelvic pain are multiple and highly variable. In other words, subjects with pain in similar regions are not homogeneous; their control system (CNS) responds differently to pain (including current pain, past history of pain, and experimentally induced pain). This is highly consistent with what is observed in clinical practice. In research experiments and clinical practice, subjects/ patients with low back, pelvic girdle, and/or groin pain of a similar distribution may present with neuromuscular patterns that have increased activation of:

- both the flexors and extensors of the trunk (co-contraction bracing or trunk-gripping);
- the flexors of the trunk only (chest-gripping);
- the extensors of the trunk (back-gripping);
- the deep and superficial muscles of the hip in a variety of patterns (butt-gripping, hip-gripping); and/or

- asymmetrical combinations of the above (1-4).

van Dieen (2007) notes that it is not possible to predict the actual neuromuscular consequence of musculoskeletal disorders. The starting point of his 'theory of contingent adaptation' is the 'indeterminacy of behavioral responses to pathology.'

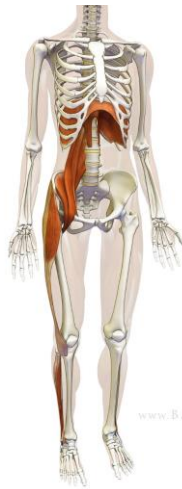Theories abound as to why these neuromuscular and structural changes occur; it has been suggested that the CNS responds/adapts to pain by increasing spinal stiffness through co-contraction bracing of the trunk muscles to prevent movements that provoke pain and to increase stability. Others suggest that the non-optimal neuromuscular patterns are pre-existing and the cause of pain. In patients with recurrent problems, it is likely a combination of reasons. What is evident from both the science and the clinic is that the healthy individual has a wide spectrum of optimal strategies to choose from for multiple tasks (Chapter 4) and can use his/her muscle system in a variety of ways. In subjects with low back pain, the spectrum becomes reduced to predominately one strategy that is used for all tasks. Performing all tasks with the same strategy (trunk-grip, chest-grip, back-grip, butt-grip, etc.) will eventually overload the passive and active system structures that are then consistently and repetitively stressed (Fig. 5.13A-C), which could be a factor in the cause of recurrent LPH pain. Note that non-optimal strategies may themselves be a cause of pain without causing significant pathoanatomical changes. Lee, 2011>>

<<researchers did rectal examinations of naive male subjects. Looking up the rectum of a subject, one of the two doctors present would casually say to the other, within earshot of the subject, that something looked cancerous inside the rectum. The other doctor would agree, and then they would observe what happened in the subject's colon. The researchers reported that commonly the colon of the subject would go into an immediate spasm. As soon as the doctors reassured the subject that he was healthy and did not have cancer, the spastic colon immediately released. This experiment illustrated how a catastrophic idea about your health can have an immediate and profound physical effect. Wise 2018>>





## Centrale factoren



- Anamnese
- Central Sensitivity Inventory
- Nijmeegse vragenlijst
- Hypertonie adductoren

16

### Centrale factoren

Of women with chronic pelvic pain, 40-60% have a history of abuse. In a study of patients managed in a specialty pelvic pain clinic, 36% had a history of sexual abuse and 30% had a history of physical abuse [37]. Whether physical or sexual abuse specifically causes chronic pelvic pain is not clear.

(Howard Pain 2012 Ch 16)

The medial arcuate ligament is continuous medially with the lateral margin of the crus, and is attached to the side of the body of the first or second lumbar vertebra. Laterally, it is fixed to the front of the transverse process of T12, and arches over the psoas muscle. Abnormal tensions in this ligament may irritate psoas, resulting in pain and spasm. Conversely psoas spasm may influence diaphragmatic mechanics (Burkill & Healy 2000, Carriere 2006).

If you find hypertonia of the adductors during the examination, this may be an indication of sexual trauma.

<<The presence of dysfunctional breathing patterns which influence pelvic function ([McLaughlin 2009](#)) and pelvic dysfunction which influences breathing patterns

([Hodges et al. 2007](#)) therefore suggests that rehabilitation of the thorax, pelvic girdle and pelvic floor will be enhanced by more normal physiological breathing patterns. This can be achieved through exercise, breathing retraining, postural reeducation, manual therapy and other means ([Chaitow 2007](#), [O'Sullivan & Beales 2007](#), [McLaughlin 2009](#)).

[Hodges et al. \(2007\)](#) observe that there is a clear connection between sacroiliac joint (SIJ) stability and respiratory and pelvic floor function, particularly in women. They suggest that if the PFM are dysfunctional, spinal support may be compromised, increasing obliquus externus activity, which in turn may alter PFM activity.

The lack of normal diaphragmatic movement in individuals with breathing pattern disorders (BPD) deprives the viscera and abdominal cavity of rhythmic stimulation (internal 'massage') which may be important for maintaining normal pelvic circulation. Pelvic pain and congestion have been correlated with chronic muscle tension, chronic hypoxia, as well as accumulation of metabolites such as lactic acid and potassium ([Kuligowska et al. 2005](#)).

[Hodges et al. \(2001\)](#) have demonstrated that, after approximately 60 seconds of over-breathing (hyperventilation), the postural (tonic) and phasic functions of both the diaphragm and transversus abdominis are reduced or absent, with major implications for spinal and sacroiliac stability.

Chaitow in Chaitow 2012 Ch. 9>>



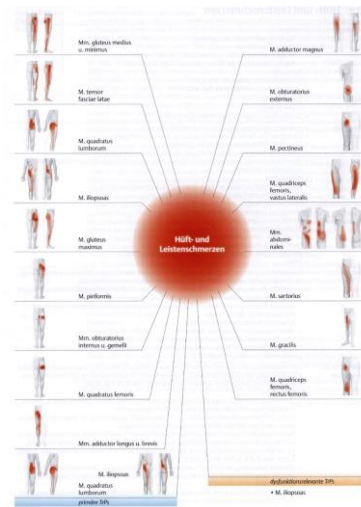
## Myofasciaal

### Liespijn:

Zeer vaak: mm adductoren longus en br

Vaak: pectineus, add magnus

Pirimaïr: ilopsoas



(Gautschi 2013)



## Superficiale fascia



18



## F01 - Iliacus

### Dysfunctie L5/S1

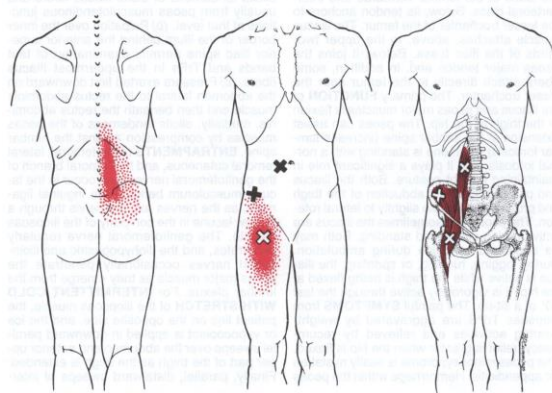


Figure 5.1. Pattern of pain (bright red) referred from palpable myofascial trigger points (Xs) in the right iliopectineal region. The essential pain reference zone is solid red; the spill-over pattern is stippled.

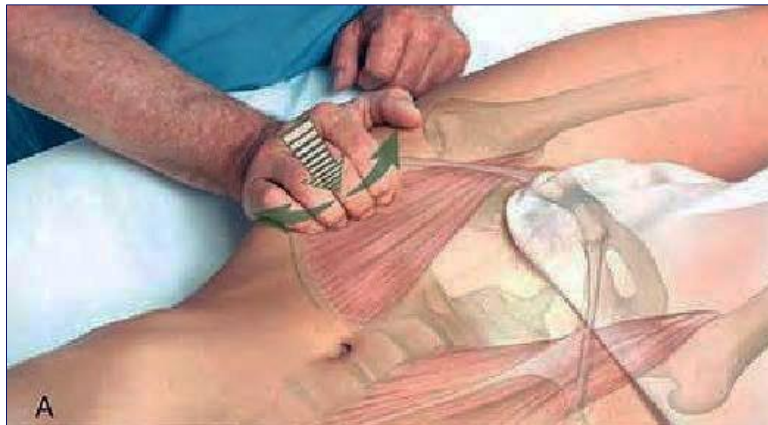
19

A TrP in the iliacus is experienced as pain in the lower abdomen, or sometimes in the groin. Often with dysfunction of L5/S1

<< Adolescent girls with pelvic distortion also frequently present with dysmenorrhea. Here the true cause is probably a dysfunction at the lumbosacral junction with TrP in the iliacus. Lewit 2010>>



## F01 - Iliacus



(Allen, 2016)

20



## F02 Psoas

P.S.O.A.S. = Primary Storer Of All Stress



Filet\_de\_bœuf / tender loin

21

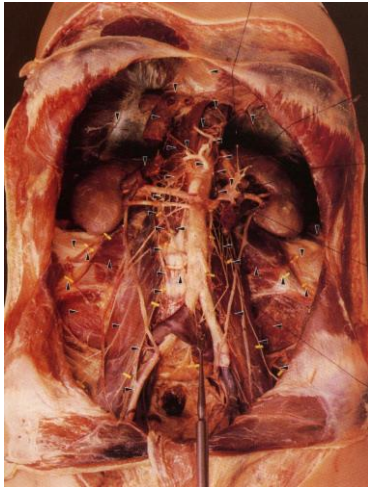
TrPs in the iliopsoas muscle refer pain to the groin area, superior part of the thigh and to the back (Figure 11.1.9). This is an important muscle since it is anatomically related to several urogenital structures and the lumbar plexus (Stepnik et al. 2006).

Psoas: connection above with lower body, the inside with the outside, the back with the front. It has an autonomous plexus, a strong relationship with the kidneys, intestines and sexuality.

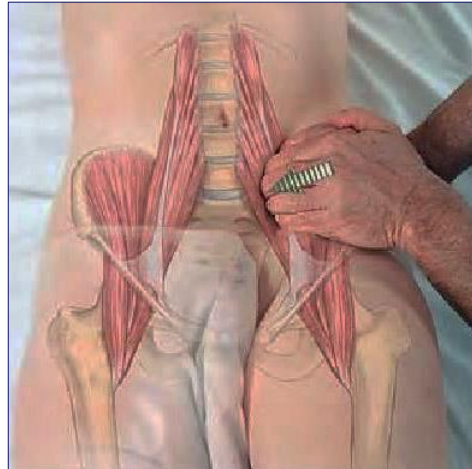
<<P.S.O.A.S. Primary Storer Of All Stress An overtight psoas pulls our back forward, spills guts downout and even pitches the head and neck forward of our body. Karrash 2012>>



## F02 - psoas



(Thiel 2008)



(Allen, 2016)

22

<< The abdominal aorta, which supplies blood to the pelvis abdomen and legs, splits into the left and right iliac arteries which follow the path of the psoas down towards the leg. Poor circulation in the feet and toes can be a common indicator of psoas problems. Sometimes the quadriceps muscles are so tight, there is no getting to the psoas until we release the quads a bit. Fitzgordon, 2013>>

<<Finding the psoas major in this way can also help you assess the relationship between the psoas major and the iliacus, as they can sometimes become adhered via the iliac fascia. In these cases it is useful to spend time differentiating them by 'swimming' your fingers into the septum to tease them apart.

To work bilaterally, use both hands and find the psoas major on both sides, using the same guidelines as above and making sure your pressure is the same from both hands. Ask your client to slowly push into their feet and roll their sacrum and lumbar vertebrae up. Then engage the psoas myofascia lightly as they roll back down, one vertebra at a time. Use the input from both hands to guide the lengthening of the tissue, to ensure it is even.

Earls 2017>>

<<Sometimes the quadriceps muscles are so tight, there is no getting to the psoas



until we release the quads a bit. Fitzgordon, 2013>>

<<The most common problem I see is the iliopsoas not gliding well over the pubis and under the inguinal ligament. This can give an impression of a short psoas, but it is not in the muscle itself, it is fibrosity in the connective tissue around the muscle as it travels under the inguinal ligament over the front of the pelvis. Test this glide. I have yet to see an untreated person where the psoas glides well on both sides. It is often bound on both. Jeffrey Burch>>



## F02 - psoas

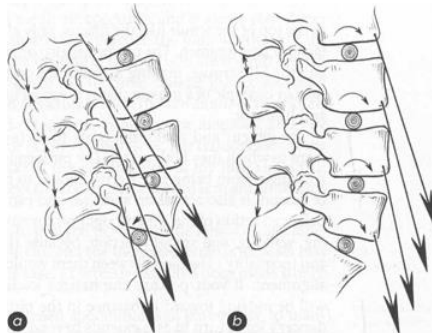


Figure 10.64 (a) Deeper fibers of the psoas major extend; (b) superficial fibers flex the lumbar spine.

23

There are different opinions about the psoas

Psoas is a triangular muscle -> variation in movement

Upper fibers can be responsible for a flatback

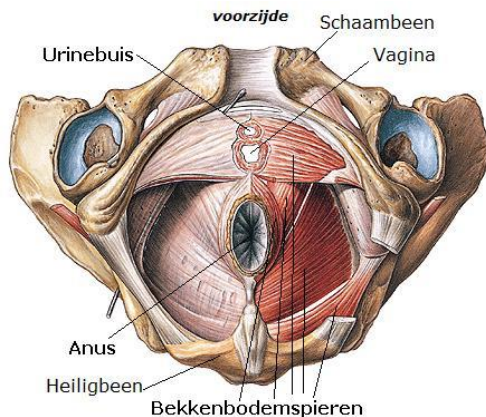
Lower fibers can be responsible for hyperlordosis.

The psoas connects the body across the front and the piriformis at the back. These two muscles, when working well, perform a balancing act that allows for successful upright posture. A problem with one of these muscles always involves a problem with the other as well.

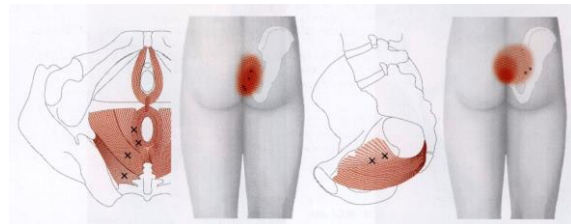
The psoas lives right next door to the bladder. Many people wake up to urinate a lot of times over the course of a night. Very often, it is a short, tight psoas pressing against the bladder that creates the environment for that to happen, and hopefully releasing can help you out of that.



## F03 - bekkenbodem



### TrP's bekkenbodem



24

<< The pelvic floor consists of several parts:

- the upper floor: the pelvic diaphragm
- the lower floor: the urogenital diaphragm and the sphincters
- the ischio-anal (ischio-rectal) fossa between both of these two 'floors'.
- In functional terms, the following can also be included as part of the pelvic diaphragm:
  - obturator, coccygeus and piriformis muscles
  - obturator membrane, infrapubic ligament and hip joint capsules
  - attachments of the adductor muscles

The innervation of the pelvic floor is supplied through the muscular branches (perineal branches) of the pudendal nerve (S3-S4) of the sacral plexus. The external anal sphincter is innervated by the inferior rectal nerve, a branch of the pudendal nerve

*Note that congestion and adhesions in the pelvis can cause reflux of the lymph in the gluteal region. A typical finding in this case is a dorsal 'fluid cushion' on the sacrum. The mobility of the pelvic organs and of the subperitoneal connective tissue should then be examined and treated. Meert 2012>>*



## Bekken – darmen / blaas

### Plasfrequentie

5-7 x/dag = normaal

Minder: dehydratie / ophoudgedrag?

Meer: diabetes / hypertone bekkenbodem

### Bristol Stool Chart

Type 1		Losse harde keutels, zoals noten (moeilijk uit te scheiden)
Type 2		Als een worst, maar klonterig
Type 3		Als een worst, maar met barstjes aan de buitenkant
Type 4		Als een worst of slang, glad en zacht
Type 5		Zachte keutels met duidelijke randen (makkelijk uit te scheiden)
Type 6		Zachte stukjes met gehavende randen, een papperige uitscheiding
Type 7		Waterig, geen vaste stukjes. Helemaal vloeibaar

25 **25**

<< Urinary Symptoms: Frequency, Urgency, Hesitancy, Dribbling, Dysuria (Burning with Urination), Nocturia (Nighttime Urination)

### Frequency and Urgency

- \* Urinary frequency in our patients ranges from annoying to debilitating.
- \* There is commonly a feeling of something always nagging in the bladder/urethra/genitals, and

typically, after patients urinate, they report that they don't feel "emptied" during or after urination and are left with the feeling of having to urinate again even though there is little to urinate.

- \* Frequency/urgency can result in the feeling of having to be near a bathroom; sometimes one can hardly hold in the urge to urinate when it arises. Some patients feel that their lives revolve around staying near a toilet.

### Nocturia (Frequent Nighttime Urination) for Men and Women

- \* Urinary urgency and frequency at night can deprive patients of sleep.
- \* Exhaustion from sleep deprivation tends to feed into the cycle of tension, pain, protective guarding, and anxiety.

### Dysuria (Discomfort, Pain, or Burning Before, During, or After Urination)

- \* Discomfort, pain, or burning during urination is associated with pelvic-floor dysfunction.
- \* When the trigger points, chronic spasm, and

myofascial contraction of the pelvic muscles are resolved, dysuria is also resolved in many of our patients.

- \* Some patients experience discomfort only after urination, not during.
- \* In a subset of individuals, dysuria can be quite painful, and urination becomes an ordeal and sets off further pain.

#### Reduced Urinary Stream and Hesitancy of Urination

- \* In men it is important to medically evaluate whether the reduced stream is caused by prostate enlargement or other issues.
- \* This symptom can be worsened when urine is held in longer than comfortable (because we speculate that the tightening of the muscles to hold in the urine can result in a kind of spasm that is slow to release upon urination).
- \* Reduced urinary stream can be a contributing symptom to low self-esteem and hypochondriasis, especially in our younger patients.
- \* When urinary symptoms are part of muscle-based

chronic pelvic pain syndrome, we have found that the flow of urine can improve after the pelvic floor is loosened.

### Discomfort or Relief After a Bowel Movement

- \* Relief after a bowel movement occurs when the tight pelvic muscles relax.
- \* Discomfort after a bowel movement can be particularly disconcerting if that post—bowel movement pain triggers symptoms more strongly for the rest of the day.
- \* Little is written about this symptom when it occurs in the absence of hemorrhoids or anal fissures, but in our experience it is common.
- \* The mechanism of defecation typically involves the filling up of the rectum with stool, which sends a signal for the internal anal sphincter and puborectalis muscle to relax and triggers the experience of urgency to have a bowel movement.
- \* Once the stool passes through the relaxed anal sphincter and out of the body, the internal anal sphincter reflexively closes.

- \* When someone has pelvic pain and exacerbation of symptoms after a bowel movement, we propose that the internal anal sphincter tends to "overdose"; we propose that the sphincter reflexively overtightens instead of resuming its normal, relaxed, resting tone.
- \* Sometimes patients experience a nagging urgency to have a bowel movement throughout the day even when they have little to evacuate.

The overtightening of the internal sphincter typically can be felt digitally

- \* Post—bowel movement pain appears to occur less frequently when someone is relaxed and not hurried, and whatever contributes to a more relaxed state during a visit to the bathroom may reduce this symptom.
- \* Resolving post—bowel movement pain in our patients tends to occur as their entire chronic pelvic muscle tension and irritability releases.

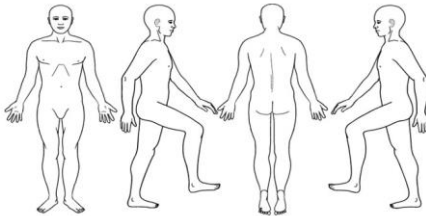
Wise 2018>>





## Anamnese formulier

Naam: \_\_\_\_\_ Datum: \_\_\_\_\_



Aard van de pijn:

VAS pijn:

VAS moe:

VAS stress:

Provocatie:

Doelen:

Meest belemmerende activiteit:

Sport:

Littekens:

Bloedingsziekte / bloedverdunders / zwangerschap / interne pathologie / medicatie

VAS voeding:

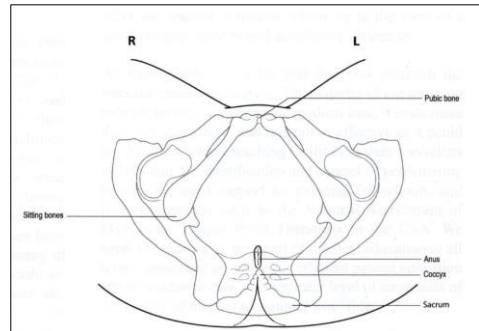
VAS slaap:

VAS beweging:

Vermindering:

Roken:

AGE:



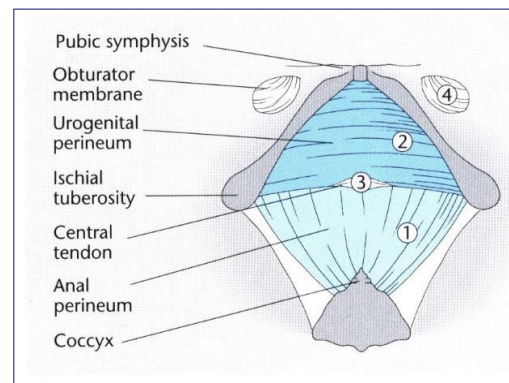
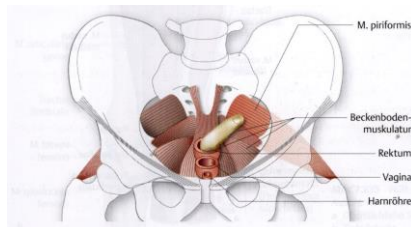
26

Extra attention for traumatic (especially sexual) experiences.

The right topography plate can be used for pelvic complaints.



## F03 – bekkenbodem / piriformis



27

You must be qualified for internal examination of the pelvic floor. Refer to pelvic physiotherapist if necessary.

### Perineum:

Just before the anus and in the middle of the eight figure is the center of the perineum. This is a key position of the pelvic floor. All connective tissue and muscle layers come together here. It is the collection point where all the power of the pelvic floor comes together. To distinguish this point from the rest of the perineum, we are talking about the center of the perineum. If you stimulate and strengthen this central point, you will find that it contains strength enough to support the entire upper body. For women this point is better developed and more clearly distinguishable than for men; for example, it plays a role if the baby's head has to be turned in the right direction at birth. Unfortunately, this is often the point where the perineum is cut preventively to prevent it from tearing too far. In that case it is of great importance that the layers grow well together again without scars. Good training, visualization and touch can be very helpful.

<<Perineal Discomfort (Pain Between Scrotum and Anus

or Vagina and Anus)

- \* The perineum is one of the most common sites of pelvic pain, is intimate, can hurt 24/7, and may be very distressing. The perineum is the place where most muscles of the pelvic floor attach, has many sources of referred pain, and can be experienced on one side or another.
- \* The perineum is often the site of bicycle-riding pain.
- \* Perineal pain can be made worse by sitting or standing.
- \* In a 2009 Stanford study of our work published in the Journal of Urology, we documented that 79 percent of our patients complained of pain in the perineum.
- \* The perineum, the anal sphincter, and the tailbone are parts of the body where patients can experience the feeling of "sitting on a golf ball."

Male:

- pain in the tip of the penis or the sense of urgency and frequency is typically created by active trigger points in the anterior (front) portion of the levator ani muscle as it attaches to the prostate. Furthermore, trigger points in this area can refer to the bladder, urethra, pressure, and

fullness in the prostate.

- Trigger points in the middle portion of levator ani can refer pain and pressure to the base of the penis, prostate, bladder, and pelvis and re-create frequency and urgency.
- Anterior Levator Ani, Inferior Portion (or Puborectalis)  
Can refer pain and pressure to the perineum, the base of the penis, and the prostate. This is one of the most common and important trigger points in male pelvic pain.
- Trigger points in the middle levator ani (iliococcygeus) typically refer lateral wall pain, perineal pain, and anal sphincter pain. Trigger points can refer forward toward the anterior levators and the prostate. Trigger points here can refer discomfort associated with a sense of prostate fullness.
- Coccygeus/Ischiococcygeus: Trigger points in this muscle typically refer pain and pressure associated with the sense of having-a-golf-ball-in-the-rectum, pain to the coccyx, and gluteus maximus. Pre- or post-bowel movement pain is often associated with the sense of having a full bowel.

- Sphincter Ani: Trigger points in this area may cause anal pain in the anal sphincter itself as well as pain going toward the front and back part of the anal sphincter. Treatment is done by gently stretching the sphincter upward in the 12 o'clock position, sideways in the 3 o'clock position, downward to the 6 o'clock position, and sideways toward the 9 o'clock position.

## **Female:**

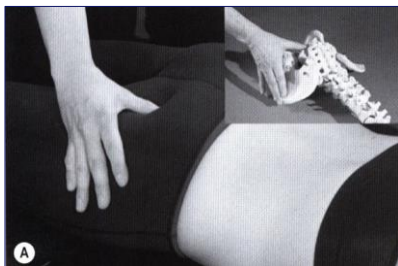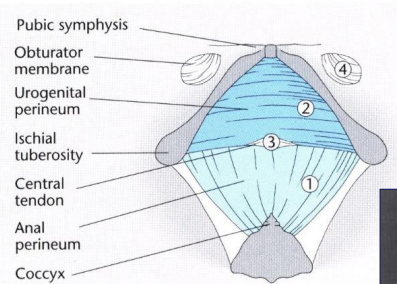
- Anterior Levator Ani (Inferior Portion): This is the part of the muscle closest to the back of the pubic bone. Trigger points can refer to the bladder, urethra, clitoris, mons pubis, vaginal lips (labium majus and minus), or vestibule (entrance) of the vagina. Trigger points referring discomfort to the bladder can be associated with a sense of urinary urgency.
- Perineal Body: Trigger points in the perineum can refer pain and sensation to the rectum, vagina, and site of palpation.
- Superficial Transverse Perineal Muscles: Trigger points in the superficial transverse perineal muscles can

refer pain and sensation to the vagina and on the site  
of palpation.

Wise 2018>>



## Palpatie – bekkenbodem



(Lee, 2011)

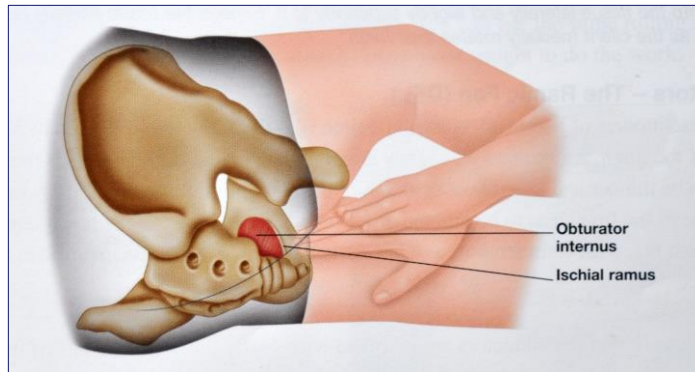


28

<< Pelvic girdle: palpation of ischiococcygeus. (A) Palpate ischiococcygeus immediately inferior to the inferior lateral angle of the sacrum and the inferior arcuate band of the sacrotuberous ligament and note the tone and presence of any tender trigger points within the muscle. (B) Ischiococcygeus can also be palpated with the patient in the supine position. Find the coccyx and then palpate for increased tone and tenderness in ischiococcygeus, which lies directly lateral to the coccyx and inferior to the inferior lateral angle.  
Lee, 2011>>



## F04 Obturatorius int



(Earls, 2017)

29

<<Piriformis and obturator internus muscles are well known as sources of chronic pelvic pain in patients, and therapeutic intervention provides clinical improvements.2,3 Kim 2015>>

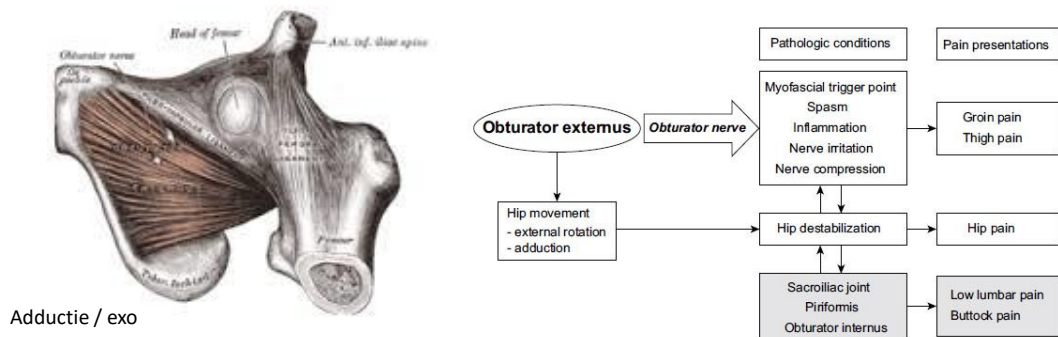
<< Trigger points in the obturator can refer pain to the perineum, outward toward the hip, or to the whole pelvic floor, both anteriorly and posteriorly. The obturator is intimate with the pudendal nerve and can refer a dull ache and burning in the pelvic floor on the side on which it is being palpated. Trigger points in the obturator can refer the golf-ball-in-the-rectum feeling, symptoms to the coccyx, hamstrings, and posterior thigh. In women, trigger points in the obturator can refer to the urethra, the vagina, and specifically the vulva and



is a very important point in the treatment of vulvar pain. In women, trigger points in the obturator can refer to the urethra, the vagina, and specifically the vulva and is a very important point in the treatment of vulvar pain. Wise 2018>>



## F04 Obturatorius ext



The obturator externus muscle as a possible pain generator in chronic pelvic pain: a proposed explanation.

(Kim 2015)

30

<<Often affected by coxarthrosis

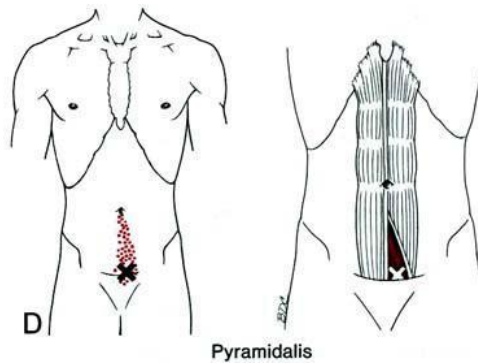
Entrapment in the obturator canal affects not only the nerve (obturator nerve), but also the blood vessel (obturator artery) -> taut bands can reduce the perfusion of the obturator artery, which supplies the head of the femur through its acetabular branch by way of the ligament of the head of the femur -> facilitates coxarthrosis.

Stretch provocation is performed by means of flexion-transverse adduction-IR of the hip; this test movement is not very specific, and it provokes not only mTrPs in the obturator externus (end-phase pain), but can also indicate femoroacetabular impingement (pain occurring during the movement phase).

Palpation and therapy: Approach 1: from the superior pubic ramus, palpate posteriorly toward the obturator foramen, (a) through the pectineus; (b) between the adductor longus and pectineus, or (c) between the pectineus and iliopsoas. Approach 2: from the lower border of the inferior pubic ramus, palpate toward the obturator foramen, (a) through or between the adductor magnus and adductor brevis, (b) through or between the adductor brevis and the adductor longus. Gautschi 2019>>



## F05 - pyramidalis



31

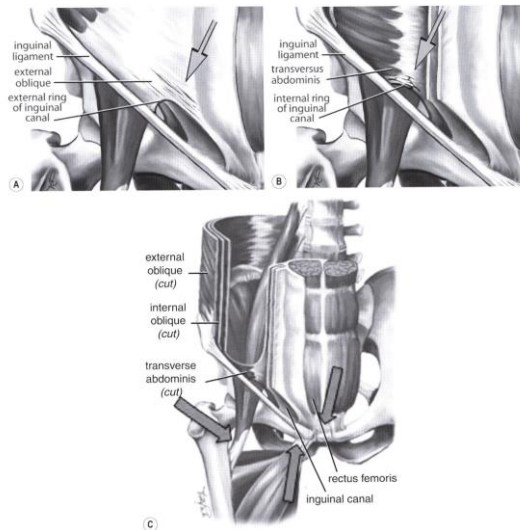
### <<Pain Above the Pubic Bone (Suprapubic Pain)

- \* Suprapubic pain is common with patients who have urinary frequency, urgency, hesitancy, and anterior symptoms.
- \* Sometimes pressing on this area can refer into the anorectal (anus and rectum) area, and bladder pain is sometimes experienced here as well.
- \* Pain can be on one side or another or in the middle.

Wise 2018>>



## Hernia inguinalis



32

<<Do not palpate heavily on the lateral side of the pubic tubercles, as there is a weakness in the fascial walls here, especially for the male of the species, and over-working here could predispose toward an inguinal hernia. Myers in Chaitow 2017 Ch 6>>



## Triggerpoints lies

### Liespijn:

**Zeer vaak:** mm adductoren longus en br

**Vaak:** pectineus, add magnus

**Primair:** ilopsoas

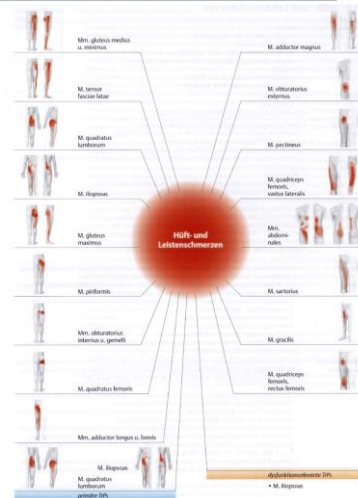
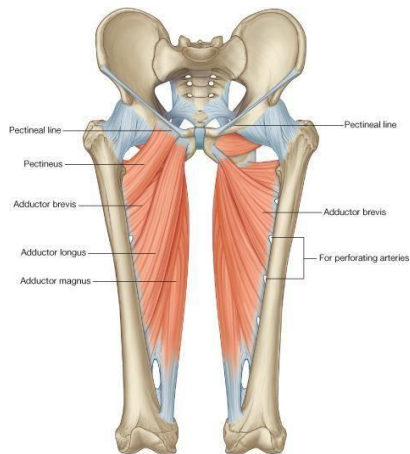


Abb. 9.43 HUP- en Laterale Femoralepijn.

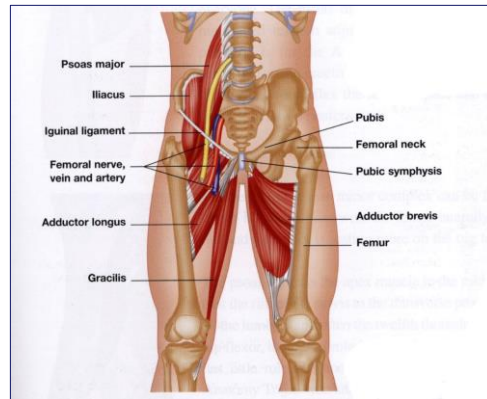
(Gautschi 2019)



## F06 - Adductoren



© Elsevier. Drake et al: Gray's Anatomy for Students - www.studentconsult.com



(Earls 2017)

34

<<All of these muscles attach around the pubic bone. But the adductor magnus, the biggest of them, has one head that attaches to one of your sit bones, the ischeal tuberosity. Interestingly, that makes this muscle responsible for not just moving your leg to the midline but also assists with internal rotation. And that ability to rotate the leg in is an absolute key to stabilizing and setting the psoas. Fitzgordon 2013>>

Pectinuous is linked as a muscle with psoas minor in 50% of the people, but fascial in 100%.

### <<Adductor Magnus

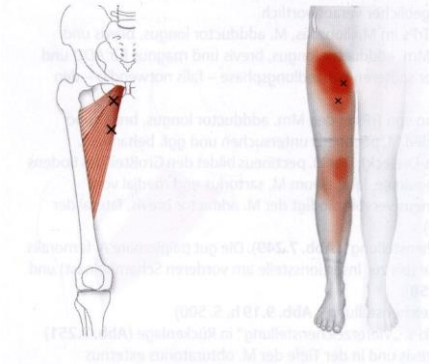
The adductor magnus is a critical muscle to check for trigger points that can refer pain throughout the pelvic floor, including the perineum, bladder, and prostate.

Trigger points in the adductor magnus can refer the

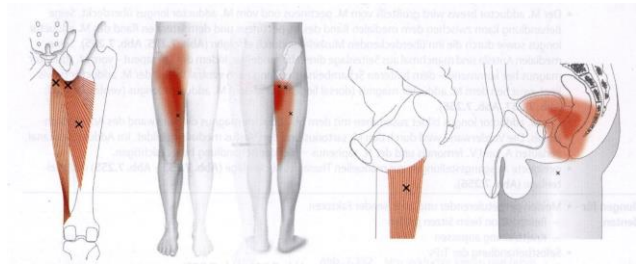
sensation of having a golf ball in the rectum. Wise  
2018>>



## F06 Adductoren



Adductor longus en brevis



Adductor magnus

(Gautschi 2013)

35

### << Pectineus:

The position of the hip assumed by the patient to avoid pain and to protect the hip expresses the activity pattern of the pectineus (ADD and flexion) -> in chronic hip problems, the pectineus is almost always affected over time.

The pectineus rarely causes limited ROM of ABD; the other adductors are usually more responsible for limited ROM.

TrPs in the pectineus usually occur in conjunction with TrPs in the iliopsoas and the adductor longus, brevis and magnus muscles -> first treat the TrPs in the synergists (the adductor longus, brevis and magus for adduction, and the iliopsoas for flexion); wait until a later treatment session to add the treatment of the pectineus — if still necessary.

If residual symptoms remain in the groin after treating TrPs in the adductor longus, brevis and magnus and in the iliopsoas, then the pectineus should be subsequently examined and treated if necessary.

Femoral triangle (trigonum femorale or Scarpa triangle): The pectineus forms the largest part of the floor of the femoral triangle, which is bordered superiorly by the inguinal ligament, laterally by the sartorius, and medially by the adductor longus. The floor of the triangle is completed medial to the pectineus by the adductor brevis, and lateral to it by the iliopsoas.



Palpation can be most easily performed by putting the patient in the "figure 4 position". The easily palpable femoral artery crosses over the pectineus muscle, which can be palpated medial to the artery (to its insertion site on the anterior ramus of the pubic bone) and lateral to the artery.

- Stretch provocation is tested by the Patrick test ("figure 4 position"); .

Suitable patient positioning for treatment of the TrPs is "figure 4 position" with the patient supine.

The adductor brevis lies under the pectineus, and the obturator externus lies even deeper.

Adductor longus and brevis:

TrPs in the adductor longus and brevis are a very common cause of pain in the groin.

The adductor longus is usually easily palpable in the proximal third; the TrPs in this area are, as a rule, easy to treat using the pincer grip.

The adductor brevis muscle is, for the most part, covered by the pectineus and the adductor longus. Its treatment can be performed between the medial border of the pectineus and the lateral border of the adductor longus, or through the overlying muscles. With the patient in the lateral position, the medial parts of the muscle can sometimes be treated directly. The therapist — starting from the adductor magnus and moving anteriorly — palpates along the posterior ramus of the pubic bone; the adductor brevis muscle lies between the adductor magnus (posteriorly) and the adductor longus (anteriorly)

Together with the adductor magnus muscle, the adductor longus forms the posterior wall of the adductor canal; the anterior wall is formed from the sartorius and the vastus medialis. The femoral artery and vein and the saphenous nerve pass through the adductor canal ->take this into account during treatment.

Adductor magnus

Very large muscle

Largely covered by the hamstring muscle group and the gracilis

Palpation of TrPs is often difficult -> "plow through" the muscle deeply using technique III to locate the points that are most sensitive to pressure, from which the patient's clinical pain is elicited

Using a wooden trigger point tool to ease the burden on the therapist's fingers

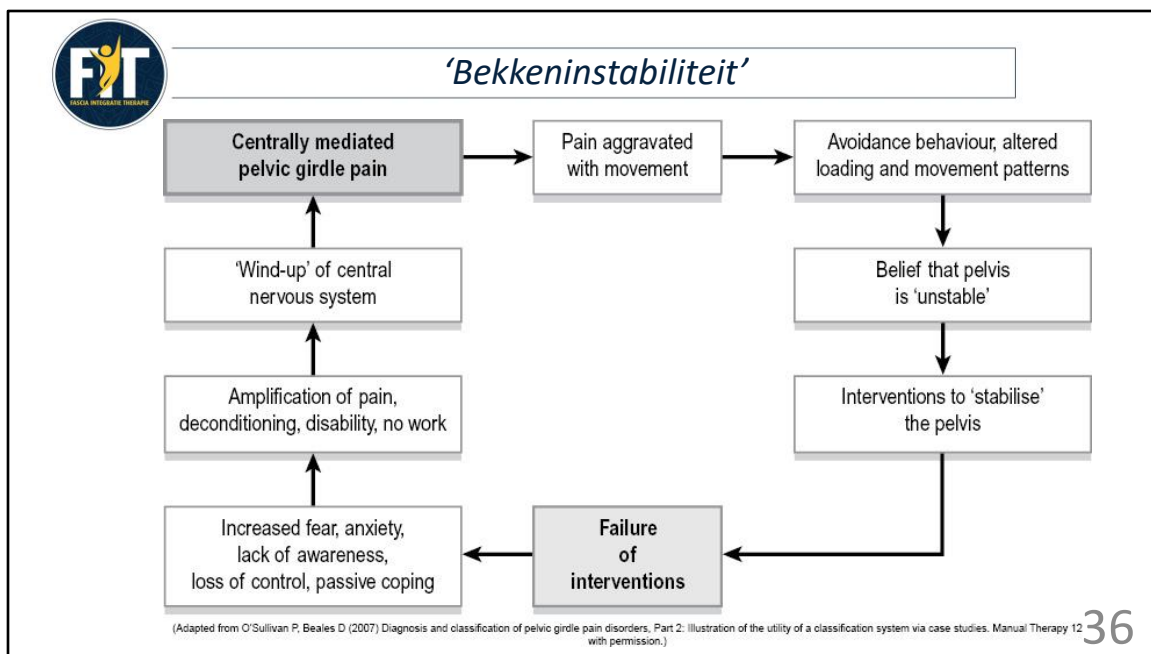
It is important to use fascial separation to separate this muscle from the hamstring muscles

Gracilis

- The only "two-joint muscle" in the adductor group

Identification and palpation of the gracilis is performed with the hip markedly abducted and the knee extended. In assuming this position, the proximal gracilis emerges clearly (because it is the only "two-joint muscle" in the adductor group), and

can be differentiated from the adjacent adductor longus and from the adductor magnus, which lies beneath it. Gautschi 2019>>



<<Doctoral research by Damen L. \* \* showed that the degree of 'laxity' of the sacro-iliac joints does not determine whether pelvic pain will occur and persist, but whether there is a difference in 'laxity' between the left and right sacro -iliac joint. Damen used a new technique at the time to measure the laxity of the sacro-iliac joints: 'doppler imaging of vibrations' (DIV). A difference in laxity, measured during pregnancy, gave a three times as high chance of maintaining moderate to severe pelvic complaints after delivery. Nugteren 2013>>

<<However, a relatively flat joint is theoretically more vulnerable to shear forces. The SIJ is anatomically protected from shear in three ways. First, the sacrum is wedge-shaped in both the anteroposterior and vertical planes and thus is supported by the innominates (see Figs 3.7, 3.8). The articular surface of the SIJ is comprised of two to three sacral segments and each is oriented differently such that when the joint is compressed shear is prevented (see Fig. 3.12) (Solonen 1957). Second, in contrast to other synovial joints, the articular cartilage of the SIJ is not smooth, but irregular, especially on the ilium, and when the joint is compressed this irregularity increases the friction coefficient of the joint (Bowen & Cassidy 1981, Sashin 1930) (see Plates 1-5). Third, cartilage-covered bony extensions (ridges and grooves, see Fig. 3.11) protrude into the joint (Vleeming et al 1990a). All three factors resist translation of

the articular surfaces when compression (force closure) is applied to the pelvis. Both form and force closure are required to balance the moment of a large external load.

Buyruk et al (1995a,b, 1999, 2002) used a Doppler imaging system combined with vibration (DIV method) to measure stiffness of the SIJs. This research was repeated and confirmed by Damen et al (2002c). Both groups were able to demonstrate that stiffness of the SIJ is variable between subjects, and therefore the range of motion is potentially variable. This research also suggests that in healthy subjects stiffness of the SIJ is symmetrical, whereas in subjects with unilateral pelvic girdle pain SIJ stiffness is asymmetrical.

In conclusion, it is known that in weight bearing the SIJs are capable of a small amount of both angular and translational motion, that the amplitude of this motion is variable between subjects, and that within one subject the motion should be symmetrical between sides. It appears that the amplitude of SIJ motion is greater in non-weight bearing positions (Lund et al 1996). Lee, 2011>>

SI joint restriction occurs far more often as a secondary phenomenon than was previously assumed. It commonly reflects muscle fixation due to movement restriction of the fibular head with a TrP in the biceps femoris, or due to restrictions of L4/L5 as a result of TrP's in the piriformis and in the pelvic floor.

Pelvic distortion is always a secondary symptom.



So, what's the plan?

Trigger point  
treatment

Relaxation!

Tissue  
mobilisation

Train the fascia



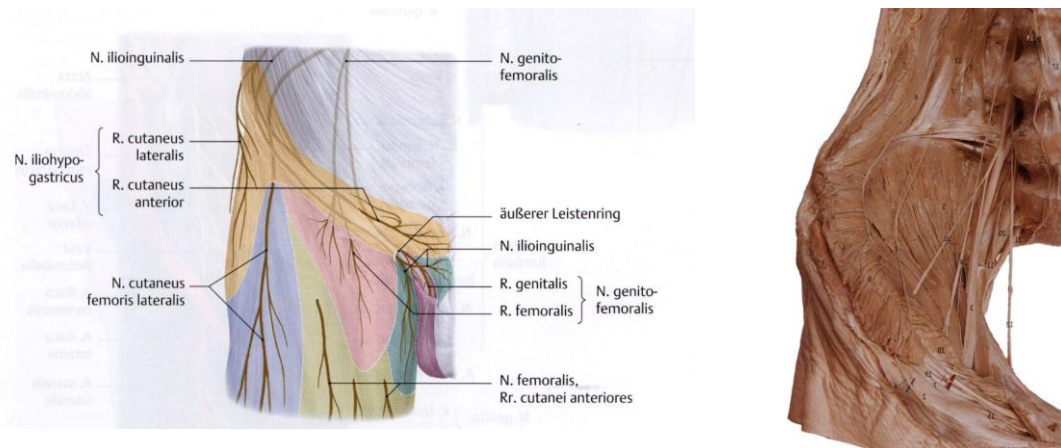
37

<<The presence of active TrPs in neck pain has previously been documented in the literature (Fernandez-de-Las-Penas C 2007, Dommerholt J. 2005, Freeman MD, 2009, Castaldo M, 2014). Active TrPs exhibit greater concentrations of inflammatory and nociceptive substances (substance P, cytokines, etc.) compared with latent TrPs (Shah JP, 2008). These substances sensitize local nociceptors suggesting an explanation for higher neck pain and lower PPTs in active TrP areas. These results would be further supported by the fact that the injection of algogenic substances has been used to mimic muscle pain and to induce pressure hypersensitivity in healthy subjects (Svensson P, 2003). Further, if the nociceptive input from the periphery is long-lasting, this may lead to an increased barrage to the central nervous system that can finally increase excitability and synaptic efficacy of neurons in central nociceptive pathways developing central sensitization and therefore lowering PPTs in distant pain-free areas (Shah JP 2008, Imamura M 2016). The fact that nociceptive stimulation of latent TrPs can induce central sensitization in healthy subjects would support this hypothesis (Xu YM 2010). The results suggest that active TrPs can contribute to the development of pain, disability and local as well as widespread pressure pain hypersensitivity in patients with neck disorders. This would support the importance of a treatment directed towards active TrPs deactivation as this may reduce pain and increase pressure pain sensitivity both locally and widespread, as previously found in

patients with shoulder pain (Hidalgo-Lozano A 2011). Castaldo 2017>>



## zenuwen



38

<<Several nerves around the groin and pelvis are vulnerable to compression: ilioinguinal; iliohypogastric; lateral femoral cutaneous nerve of the thigh; genitofemoral; obturator and pudendal.

The ilioinguinal, iliohypogastric and genitofemoral nerves originate from the first lumbar nerve (L1) but the genitofemoral receives additional input from L2 or L3. There is considerable anatomic variation in the origin and course of these nerves as well as an overlap of their cutaneous distributions ([Aszmann et al. 1997](#), [Akita et al. 1999](#), [Rab et al. 2001](#)). The ilioinguinal branch passes through the inguinal canal, becoming fairly superficial near the superficial inguinal ring, and continues to supply the root of the penis (or labia majora), anterior scrotum, and medial thigh, as does the genitofemoral nerve. The iliohypogastric further divides into two branches: the anterior cutaneous, which carries cutaneous sensation from the lower abdominal and groin region medial to the ASIS; and the lateral cutaneous branch, which receives sensation from the lateral thigh and gluteal region ([Morelli & Weaver 2005](#)). In addition to these sensory distributions, the ilioinguinal and iliohypogastric nerves provide motor innervations to the lower abdominal musculature. Taylor in Chaitow 2012 H6>>

- Ilioinguinal (L1)
- Iliohypogastric (L1)
- lateral femoral cutaneous nerve
- genitofemoral (L1,L2,L3)
- pudendal (L2-L4) loopt door levator ani
- femoral nerve: hip joint, iliofemoral ligament, superior capsule),
- obturator nerve: pubofemoral ligament, adductoren kan klem in foramen obturatorium in verdikte fascia over add brevis
- superior gluteal nerve: superior and lateral part of the joint capsule, gluteus medius and minimus)
- the nerve to the quadratus lumborum: posterior capsule, ischiofemoral ligament
- The spinal nerves L2, L3 and L4 can refer pain to the groin or anterior thigh

Besides affecting respiratory excursion, dysfunction of the 12th rib may affect the lateral arcuate ligament, resulting in irritation of the iliohypogastric or ilioinguinal nerves that pass under it; 'this may present as paresthesias or radiating pain over the anterior aspect of the thigh and groin with running activities'.

<< The matrix of areolar connective tissue also serves to deposit collagen for the formation of scar tissue. Commonly, women with CPP have undergone laparoscopic investigation as an attempt to identify pain generators. The trochar (a surgical instrument) may have been used through the umbilicus, in the suprapubic region, or other lower abdominal sites. Formation of scar tissue here can directly create restriction of the ilioinguinal, iliohypogastric and genitofemoral nerves ([Howard 2000](#)). Peri-umbilical and suprapubic subcutaneous panniculosis secondary to incisions have been associated with urinary urgency, frequency and dysuria ([Fitzgerald & Kotarinos 2003](#)). Prendergast in Chaitow 2012 H11.2>>

<< Entrapment of the ilioinguinal, iliohypogastric and genitofemoral nerves may result in groin pain or lower abdominal pain that can radiate to the genitals. These nerves can be injured by direct trauma including abdominal surgery such as caesarean section, transvaginal tape for stress incontinence surgery and hernia repairs for overzealous training of the abdominals ([Starling & Harms 1989](#), [al-Dabbagh 2002](#), [Murovic et al. 2005](#), [Whiteside & Barber 2005](#), [Vervest et al. 2006](#), [van Ramshorst et al. 2009](#)). Tenderness is often noted 2–3 cm inferior-medial to the ASIS, and hip extension usually produces increased pain or hypoaesthesia in the nerve's distribution ([Morelli & Weaver 2005](#)).

Taylor in Chaitow 2012 H6>>

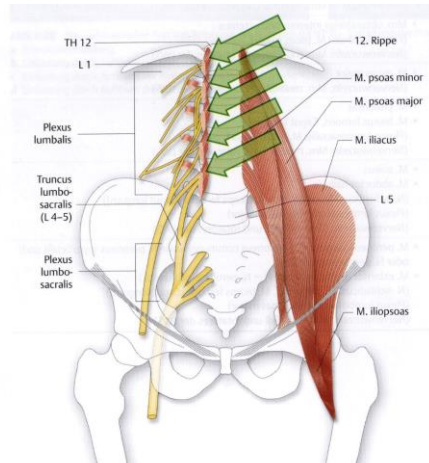
Besides affecting respiratory excursion, dysfunction of the 12th rib may affect the lateral arcuate ligament, resulting in irritation of the iliohypogastric or ilioinguinal nerves that pass under it; 'this may present as paresthesias or radiating pain over the



anterior aspect of the thigh and groin with running activities’.



## Plexus lumbalis



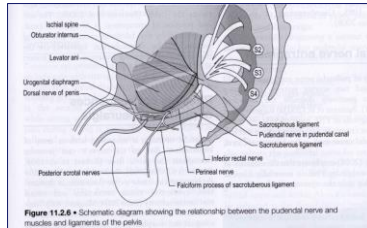
- Relatie met QL, iliocostalis, psoas en diafragma
- Check TLO

39

<<The lumbar plexus is a spinal plexus embedded in the psoas, permitting intercommunication between the lumbar plexus and the spinal nerves which emerge from the spine where the psoas attaches. Connections from the lumbar plexus to the autonomic system are extensive and intimate. Restricted movement or other mechanical interference in the psoas thus affects the general metabolic level, since this is monitored by the autonomic system as a whole Rolf>>

<<Furthermore, the thoracolumbar junction (T10-L2) can, when stimulated, result in pain perceived in the pelvis, and will also need to be evaluated in patients with chronic pelvic pain (CPP). Jones in Chaitow 2012 H 2.1>>

<<Besides affecting respiratory excursion, dysfunction of the 12th rib may affect the lateral arcuate ligament, resulting in irritation of the iliohypogastric or ilioinguinal nerves that pass under it; 'this may present as paresthesias or radiating pain over the anterior aspect of the thigh and groin with running activities'. Chaitow in Chaitow 2012 Ch 9>>



- Pain along the anatomical distribution of the pudendal nerve;
- The pain aggravated by sitting (but not on toilet)
- The patient is not awakened at night by the pain;
- There is no objective sensory loss on clinical examination;
- The pain is improved by an anaesthetic pudendal nerve block.
- Urinary dysfunction, bowel dysfunction, sexual dysfunction

- Obstipatie
- Intensieve squats
- Paard rijden
- Veel zitten
- Operaties
- Viscero-somatische reflex

Check bekkenbodembodem!

40

## <<The pudendal nerve in chronic pelvic pain

As discussed in Chapter 2, the pudendal nerve supplies the majority of the pelvic floor musculature, the skin of the genitals and peri-anus, and a portion of the rectum, vagina and urethra (for a comprehensive review see Hibner et al. 2010). It is a mixed nerve, featuring both autonomic and somatic components; therefore, it carries motor, sensory and autonomic fibres affecting both the afferent and efferent pathways (Gray & Williams 1995). Due to its autonomic fibres, a patient with pudendal neuralgia could experience sympathetic symptoms such as an increase in heart rate, decreased mobility of the large intestine, constricted blood vessels, dilated pupils, piloerection, perspiration, or an increase in blood pressure (Reitz et al. 2003).

The pudendal nerve arises from the sacral nerve roots 2, 3 and 4 and has three branches: the perineal nerve, the inferior rectal nerve and the dorsal nerve to the clitoris or penis (Robert et al. 1998, Benson & Griffis 2005) (Figure 11.2.4). It runs through three main regions: the gluteal region, the pudendal canal and the perineal

region (Thoumas et al. 1999).

There are four primary mechanisms from which pudendal neuralgia can develop. The first is via a tension injury. This occurs when the pudendal nerve is over stretched or repetitively stretched to the point of injury. Common examples include constipation, strenuous squatting exercises (see Chapter 6) and childbirth (Kiff et al. 1984, Snooks et al. 1990).

The second mechanism is through compression. Horseback riding, or prolonged sitting compress the pudendal nerve creating an ischaemic environment which eventually leads to a loss of conduction (see discussion of cycling in Chapter 6). If the nerve is chronically compressed, it results in venous stasis, increased vascular permeability, oedema and scar formation (Benson & Griffis 2005).

The third mechanism of injury is surgical insult or acute injury. Occasionally the pudendal nerve can incur injury during surgical procedures such as pelvic reconstruction procedures or hysterectomies. In rare cases, the pudendal nerve can be injured after a fall (Benson & McClellan 1993).

Lastly, pudendal neuralgia can develop due to the visceral–somatic interaction.

Through this reflex, visceral disturbances, such as chronic bladder infections and chronic yeast infections, can contribute to pudendal neuralgia (Head 1893, Bischof & Elming 1963, Beal 1985, Giamberardino et al. 2005, Giamberardino 2008).

Common symptoms of pudendal nerve dysfunction include pain with sitting, urinary dysfunction, bowel dysfunction, sexual dysfunction, burning, shooting, stabbing genital and/or anal pain, feeling of fullness in the rectum or vagina, and decreased pain while sitting on a toilet (Robert et al. 1998).

We should mention the concept of the pudendal nerves being compressed, stretched or entrapped in the pelvis as a potential cause of chronic pelvic pain. There are five essential diagnostic criteria (Stav et al. 2009):

Pain along the anatomical distribution of the pudendal nerve;

The pain aggravated by sitting;

The patient is not awakened at night by the pain;

There is no objective sensory loss on clinical examination;

The pain is improved by an anaesthetic pudendal nerve block.

Common symptoms of pudendal nerve dysfunction include pain with sitting, urinary dysfunction, bowel dysfunction, sexual dysfunction, burning, shooting, stabbing genital and/or anal pain, feeling of fullness in the rectum or vagina, and decreased pain while sitting on a toilet (Robert et al. 1998). The pain during sitting is secondary to the irritated or inflamed pudendal nerve being compressed; hence, when sitting on a toilet, the pain is decreased because the same area is not being compressed.

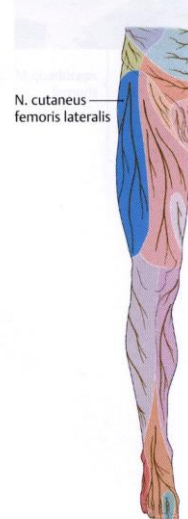
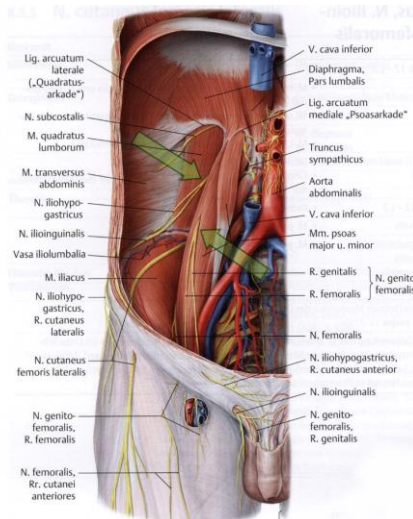
Urinary dysfunction can include hesitancy, urgency, frequency, dysuria and nocturia (Fitzgerald & Kotarinos 2003). Bowel dysfunction can include dyschezia and

constipation. Sexual dysfunction for women can include dyspareunia, dysorgasmia and aorgasmia (Basson et al. 2010); for men, post-ejaculatory pain or erectile dysfunction. The feeling of fullness in the vagina or rectum is a result of pelvic floor muscle hypertonus. When irritated, the pudendal nerve causes hypertonus of the muscles it innervates.

Any muscle and/or tissue and/or structure innervated by an affected nerve may begin to generate pain (Butler 2004). For example, a patient with connective tissue restrictions in the territory of the pudendal nerve may experience sharp, stabbing vaginal or urethral pain with increasing degrees of hip flexion. This is because the nerve must lengthen when the hip flexes; if the tissue is restricted the nerve will not be able to lengthen and the adverse tension results in neuralgic pain in the territory of the nerve. Consequently, because the and/or perineal portions of the pudendal nerve innervate the distal third of the urethra a patient may subsequently feel urethral burning. In terms of bowel function, it is not uncommon for patients with CPP to experience constipation. Connective tissue restrictions affecting the pudendal nerve can also cause neuralgia symptoms, as the restrictions will restrict the neural mobility required for lengthening when a person strains. As a result, a patient may feel neuralgic symptoms in the territory of the nerve, either immediately or with a delayed onset (Holey 1995). Prendergast in Chaitow 2012 H11.2>>



## Meralgia paraesthetica



41

The lateral cutaneous femoral nerve traverses the lateral end of the inguinal ligament. Due to increased tension in the iliopsoas and TFL the inguinal ligament itself becomes tense, producing compression on the nerve.

<< Compression of the lateral femoral cutaneous nerve of the thigh or meralgia paraesthetica can occur as it passes under or through the inguinal ligament resulting in a persistent burning sensation, tingling or aching pain, and hypersensitivity or hyposensitivity in the anterolateral aspect of the thigh ([Moucharafieh et al. 2008](#)). In addition to sportsmen such as squatting rifle team members and athletes who sustain acute trauma to the area, it has been noted in women who sit for prolonged periods with the involved leg underneath the body ([Morelli & Weaver 2005](#)) and more recently in wearers of tight low-cut trousers ([Moucharafieh et al. 2008](#)). Taylor in Chaitow 2012, H6>>

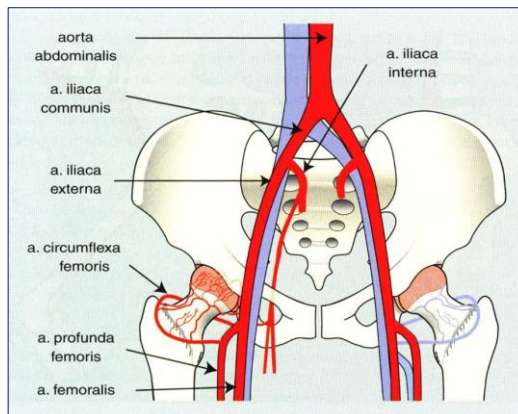


## Bloedvaten

Ouderen: artherosclerose  
Jongeren: sporten als:  
wielrijden, skaten,  
langlaufen, schaatsen

Check:

- Psoas



42

<< The abdominal aorta, which supplies blood to the pelvis abdomen and legs, splits into the left and right iliac arteries which follow the path of the psoas down towards the leg. Poor circulation in the feet and toes can be a common indicator of psoas problems.

Sometimes the quadriceps muscles are so tight, there is no getting to the psoas until we release the quads a bit. Fitzgordon, 2013>>

<< Chapter 7

People often don't think about vascular causes because young athletes almost never show vascular abnormalities such as atherosclerosis. Nonetheless, it is important for cyclists, skaters, cross-country skiers and skaters to include vascular insufficiency in the differential diagnosis. But preferably one in five top cyclists is limited in performance due to leg pain due to vascular insufficiency in one or two legs

### Etiology

Stenosis of blood vessels in the elderly is usually caused by atherosclerosis. However, atherosclerosis is rare in young athletes. In young athletes, stenosis of an iliac artery is usually caused by a completely different phenomenon: the nodding of an iliac artery during flexion of the hip joint (O Figure 7.2). As with the kink of a garden hose,

the iliac artery can bend to such an extent that it blocks blood flow. The risk sports are characterized by endurance loading with repetitive hip bending, such as cycling, rollerblading, skating and cross-country skiing.

Often, frequent kinking of the artery causes abnormalities on the inside of the blood vessel over time. The intravascular abnormality is characterized histologically by a connective tissue layered thickening of the intima. It is a reaction of the vessel wall to hemodynamic and mechanical stress and is known as endofibrosis

Stenosis of iliac arteries in young (top) athletes is usually caused by nodding of the artery during flexion of the hip joint.

Vascular abnormalities in endofibrosis are often eccentric in the blood vessel. In about 90% of the cases, endofibrosis occurs in the iliac externa, 5% in the iliac communis and 10% in the a. Femoralis. Often there is more than one affected location with variable combinations of kinking and intravascular abnormality.

The size of the iliopsoas m

The iliac arteries are located at the front of the iliopsoas m (Q Figure 7.2).

Hypertrophy of this muscle can lead to an anterior displacement of the artery. The farther the artery is to the ventral location, the greater the risk of kinks. For cyclists with vascular problems we often see that tightening the m. Iliopsoas reinforces the buckling. " It may therefore not be wise to do strength training for the iliopsoas if this is not necessary for the sport that you practice.

To reduce air resistance during cycling, the (top) athlete will pursue an aerodynamic posture; the back is held horizontally, which is only possible if the hip joints are bent considerably. This alternate flexing of the hips usually occurs naturally as the heterolateral foot pushes the pedal down. Cyclists and their coaches often try to generate extra power by 'pulling' the pedals with their feet when raising the pedals. With the current 'click pedals' that is quite possible. The m. Iliopsoas will hereby contradict. However, ultrasound doppler examination shows that contraction of the iliopsoas often enhances kinking and then immediately causes a reduction in blood flow of the leg. Such a technique - whereby the hip is forcefully bent while cycling - must therefore not be recommended. Another study has shown that top cyclists improve their performance by developing a stronger downward force and not an upwardly directed pull. <sup>TM</sup>

### 3 Symptomatology

Cyclists with sport-related stenosis of the iliac arteries generally exhibit symptoms similar to those of an intermittent claudication with symptoms that arise when cycling above a certain speed threshold and that quickly (within minutes) disappear into rest, such as: ~ leg pain;



- a feeling of loss of strength in the leg; a feeling of cramp;  
said symptoms are diffuse in different muscles and are not limited to one muscle or tendon. Approximately 60% of the people with the aforementioned symptoms have an stenosis of an iliac artery. Nugteren 2013>>



## F07 – lig. sacro-tuberale

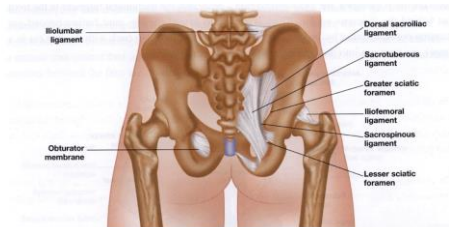
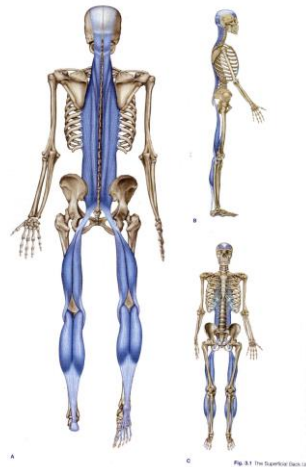

Figure 6.10: Pelvis with ligaments, posterior view.

(James Earls 2017)



(Thomas Myers)

43

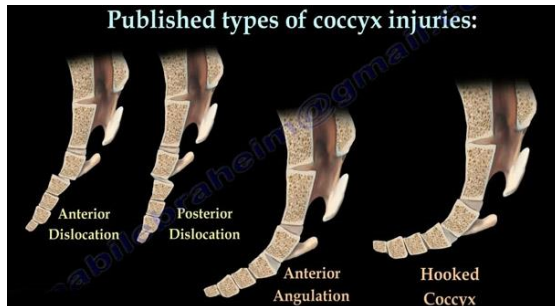
The balance of the pelvic structures can be profoundly affected by TrPs in the sacrotuberous ligament, resulting in low back pain and postpartum pelvic pain. In increasing compression the biceps femoris and gluteus maximus muscles play a role (Vleeming et al. 1989a,b, 1992b 1996; DonTigny 1990; Vleeming 1990; Van Wingerden et al. 1993). Both muscles are attached to the sacro-tuberous (and partially the sacrospinous) ligament which functionally bridges the SI joint. Obviously, pain in the area of the SI joints is not necessarily a local problem; it can be symptomatic of a failed load transfer system (Snijders et al. 1993a, b).

<<Hackett referral pain patterns include hip joint ligament referral down the leg to the big toe, sacrotuberous and sacrospinous ligaments referring pain to the heel, and the iliolumbar ligament referring pain into the groin and vagina, with the acknowledgement that the iliolumbar ligament can cause any unexplained vaginal, testicular, or groin pain.

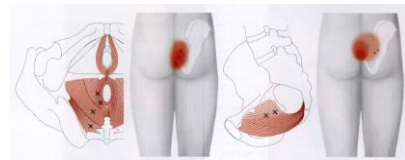
The balance of the pelvic structures can be profoundly affected by TrPs in the sacrotuberous ligament, resulting in low back pain and postpartum pelvic pain. Starlanyl 2013>>



## Coccygodynie



TrP's bekkenbodem en Gmax



20% ontstaan door trauma

Meest frequent: lateroflexie Li + rotatie Re

44

Palpation of a painful coccyx can be more difficult than might be expected. The problem here is one of myotendinosis resulting from tension of the gluteus maximus and a TrP in the levator ani, which can be palpated quite easily through the rectum.

Patients often report pain at the coccyx when what they are experiencing is in fact referred pain from other pelvic structures, in which case pain points will also be found laterally (pelvic floor, lower SI)

In the majority of cases where the coccyx is tender to palpation, patients report pain is not in the coccyx itself but in the lower back. In low-back pain, on the other hand, about one-fifth of patients experience coccygeal tenderness on palpation. The opposite is also true: reports of coccygeal pain may in fact be attributable to painful lower sacroiliac joint dysfunction, a painful ischaeal tuberosity, a TrP in the coccygeus muscle (pelvic floor), or exceptionally even pain referred from the hip. In such cases, however, tenderness does not involve the tip of the coccyx itself but rather one side of the coccyx only. Falls on the coccyx play a negligible role in chronic coccygeal pain (20%).

The treatment of choice is MET of the gluteus maximus, during which the levator ani also contracts and relaxes at the same time.

Based on clinically experience and on the therapeutic results it can be assumed that tension in the gluteus maximus and the levator ani is the main cause of a tender coccyx, that is it represents a tendomyopathy of these muscles.

A coccyx that is tender to pressure should never be ignored, because it is a considerably more frequent cause of low-back pain than coccygodynia. Palpation of the coccyx should therefore be carried out when diagnosing low-back pain.

Palpation of a painful coccyx can be more difficult than might be expected. The problem here is one of myotendinosis resulting from tension of the gluteus maximus and a TrP in the levator ani, which can be palpated quite easily through the rectum.

A tender coccyx is always ventrally curved. The pain is typically on the ventral surface of the tip, so it is necessary to feel around for the ventrally curved coccyx, which produces resistance from the gluteus maximus. Mere touch is enough to provoke pain. Any strong pressure here is always painful and therefore misleading; only pain experienced at the tip of the coccyx is diagnostically useful. Patients often report pain at the coccyx when what they are experiencing is in fact referred pain from other pelvic structures, in which case pain points will also be found laterally (pelvic floor, lower SI)

Most characteristically, however there are TrP's in the levator ani, but these can only be detected on examination per rectum.

A painful coccyx is always curved ventrally, a coccyx that is straight and points caudally is never painful

• Glomeriform arteriovenular anastomosis: the shunt is long and intertwined and is surrounded by a capsule of connective tissue (eg- Fig. 1-10b). There are particularly large anastomoses of this type in the fingertips, also called 'Hoover-Grosser organs'. There is another at the tip of the coccyx, the glomus coccygeum.

Mechanical tensions in the connective tissue surrounding the anastomosis, congestion around the capillary system and imbalances of the autonomic system can lead to functional errors and the unphysiological activation or closing of arteriovenular anastomoses.

<< The fifth joint in the pelvis is located between the sacrum and the tailbone. The tail bone can move forward and back through this joint, which causes the tension on the pelvic floor muscles to change. A certain degree of mobility is also possible between the individual vertebrae of the tailbone. In some cases, a fall on your rear may cause the tailbone to fold forward. This has consequences for the pelvic floor, since a large number of muscles are attached to the tailbone. The tailbone and the tailbone sacrum joint sometimes tend to calcify with age, but good pelvic floor training can prevent this. The training is conducive to the elasticity and mobility of the pelvis and stimulates an active sex life. Franklin 2002>>

<< Pain in the coccyx is referred as coccydynia. The pain aggravates in weight bearing i.e. sitting. Total 48 persons with coccydynia diagnosed clinically were recruited and randomly assigned into one of the 3 groups. Experimental group I were treated by stretching of piriformis and iliopsoas muscles, experimental group II were treated by stretching of piriformis and iliopsoas muscles and Maitland's rhythmic oscillatory thoracic mobilization over the hypomobile segments and the conventional group were treated by seat cushioning b Sitz bath b Phonophoresis. All participants underwent an initial baseline assessment for Pressure Pain Threshold (PPT) by using modified syringe algometer and pain free sitting duration. All the subjects were advised to minimise sitting posture and use a seat cushion. Treatment was given for 3 weeks, 5 sessions per week and post-treatment evaluation was done after completion of 3 weeks. Follow up evaluation was done after 1 month.

Data analysis: The data was analyzed by using 3 3 ANOVA. Tukey's HSD post-Hoc analysis was used for all pair wise comparison.

Results: The overall results of the study showed that there was significant improvement in pain pressure threshold and pain free sitting in both the experimental groups with treatment and improvement continued after cessation of therapy, whereas the conventional group did not improve significantly. Mohanty 2017>>

<< Coccyx (Tailbone) Pain (Coccygodynia/Coccydynia)

- \* Tailbone pain is common. It is typically referred pain from the pelvic floor or muscles attached to the tailbone and is not from the tailbone itself.
- \* Some patients we have seen who had their tailbones removed typically felt no relief.
- \* coccygectomy (surgical removal of the tailbone) has typically failed to help anyone with pelvic pain.
- \* Coccyx pain is often related to post—bowel movement pain, sitting pain, and rectal pain.